

Unusual clinical manifestations in Israeli ruminant populations infected with Orbiviruses

Velizar Bumbarov, Natalia Golender, Diza Rotenberg and Jacob Brenner*

Department of Virology, Kimron Veterinary Institute, Bet-Dagan, 50250 Israel

*Corresponding author at: Department of Virology, Kimron Veterinary Institute, Bet-Dagan, 50250 Israel.
Tel.: + 972 3 967661, e-mail: brennerjacovet@gmail.com.

Veterinaria Italiana 2016, 52 (3-4), 343-351. doi: 10.12834/VetIt.641.3154.2

Accepted: 09.07.2016 | Available on line: 30.09.2016

IV International Conference on *Bluetongue and Related Orbiviruses*. November 5-7, 2014 - Rome, Italy - Selected papers

Keywords

Bluetongue,
Israel,
Orbiviruses,
Particular clinical
manifestations,
Ruminant.

Summary

Orbiviruses, some of which are virulent in ruminant species, are transmitted by blood-sucking insects. They can cause the smallest blood vessels to leak, leading to oedema, which is presented as Bluetongue (BT) and/or Epizootic haemorrhagic diseases (EHD). Other clinical manifestations include big-muscle necrosis, excessive scialorrea, and coronitis. Pathology and laboratory testing can confirm the involvement of orbivirus. Bluetongue infection in naïve sheep can elicit the 'classical signs' of the disease and, therefore, can warn of Bluetongue virus' (BTV) attacks and of increased vector activity. In 2006, infection of cattle by serotype 7 of the Epizootic haemorrhagic disease virus (EHDV) was detected in Israel, with lesions clinically identical to those of BT disease in sheep. In 2006, serotype 15 of the BTV (BTV-15) was isolated in Israel from sheep with acute BT. In 2008 clinical BT in cattle was reported and confirmed in Israel. To date, additional serotypes (BTV-2, BTV-4, BTV-5, BTV-8, BTV-12, BTV-16, and BTV-24) have been reported, of these BTV-5, BTV-8, BTV-12, and BTV-24 were isolated for the first time in the region. Some of these serotypes have been detected in animals with simultaneous double/triple infections with different BTV serotypes, so that reassortment may also occur during these simultaneous infections. The use of local strains for the development of inactivated or subunit vaccines would however help to ensure antigenic matching. Various changes in orbiviral diseases occurred between 2006 and 2013 in Israel, and similarities and differences between Israel and Europe have been reported in this study.

Particolari manifestazioni cliniche nei ruminanti affetti da Orbivirus in Israele

Parole chiave

Bluetongue,
Israele,
Manifestazioni cliniche
specifiche,
Orbivirus,
Ruminanti.

Riassunto

Gli *Orbivirus* sono trasmessi da insetti ematofagi. Sono in grado di causare lesioni ai capillari provocando edemi tipici della Bluetongue (BT) o della Malattia emorragica epizootica (EHD). Altre manifestazioni cliniche delle due patologie sono la necrosi dei muscoli lunghi, la scialorrea e la coronite. Il quadro clinico e i test di laboratorio possono confermare l'infezione da *Orbivirus*. L'infezione da Bluetongue in ovini naïve (privi di copertura immunitaria) in genere provoca i "sintomi classici" della patologia, indicandoci la presenza del virus della Bluetongue (BTV) e un incremento dell'attività dell'insetto vettore. Nel 2006, in Israele, è stata identificata un'infezione nei bovini causata dal sierotipo 7 del virus della Malattia emorragica epizootica (EHDV) che ha evidenziato lesioni cliniche identiche a quelle della BT negli ovini. Nello stesso anno, in Israele, è stato isolato il sierotipo 14 (BTV-14) da ovini con infezione acuta di BT e, nel 2008, sono stati riscontrati e confermati segni clinici della presenza di BT in bovini. Ad oggi sono stati isolati BTV-2, BTV-4, BTV-5, BTV-8, BTV-12, BTV-16 e BTV-24, tra questi: BTV-5, BTV-8, BTV-12 e BTV-24 per la prima volta in Israele. Alcuni di questi sierotipi sono stati individuati contemporaneamente in uno stesso animale con il possibile verificarsi di fenomeni di riassortimento. Per assicurare una buona risposta immunitaria i vaccini dovrebbero essere prodotti usando ceppi locali di BTV. Tra il 2006 e il 2013 si sono verificati molteplici cambiamenti nelle patologie da *Orbivirus* in Israele, lo studio descrive le similitudini e le differenze di queste infezioni con quelle verificatesi in Europa.

Introduction – Orbiviral infections in domestic ruminants

Bluetongue (BT), Epizootic haemorrhagic disease (EHD) and Ibaraki disease (ID) are all caused by orbiviruses. Ibaraki virus is recognized as a strain of EHD virus (EHDV) serotype 2, and it shares cross-reactive epitopes with other EHDV strains/serotypes (Nara-Pereira *et al.* 2000). Conversely, Bluetongue virus (BTV) (the prototype orbivirus) represents a distinct virus species and shows little if any serological cross-reaction with EHDV (Campbell *et al.* 1978). Generally, BTV and EHDV are thought to be transmitted by the same *Culicoides* vector species. Consequently, there are overlapping of geographic zones of infection in countries that suffer from the activity of both of these viruses (Foster *et al.* 1980, Kedmi *et al.* 2011, Yadin *et al.* 2007, Yadin *et al.* 2008).

Bluetongue virus

The BTV is the type species of the genus *Orbivirus*, within the family *Reoviridae*. Currently, 27 serotypes of BTV have been identified, according to the specificity of interactions between neutralizing antibodies and the more variable components of the virus outer capsid, specifically the VP2 protein (Hofman *et al.* 2008, Maan *et al.* 2007, Maan *et al.* 2008, Roy *et al.* 1992). The BTVs are transmitted by certain *Culicoides* species (Mellor *et al.* 2000, Purse *et al.* 2005) and can infect all ruminants (MacLachlan *et al.* 2009, Schwartz-Cornil *et al.* 2008).

Clinical signs of BTV infection are usually confined to sheep, especially naïve improved meat, and wool breeds, which may develop BT. Elbers and colleagues (Elbers *et al.* 2008a, b, c, Elbers *et al.* 2009) introduced the concept of “BT-attributed clinical signs” in their study of the epidemiology of BTV-8 infection across Europe. These signs include fever, anorexia, dysphagia, ulcerative, and necrotic lesions of the oral mucosa, hyperaemia and oedema of the conjunctival mucosa, sore muzzle, hyperaemia of the teats and udder, haemorrhage, dehydration, and lameness (Darpel *et al.* 2007, Eschbaumer *et al.* 2010, Jeggo *et al.* 1987, Muller-Doblies *et al.* 2007, Pardon *et al.* 2010, Thiry *et al.* 2006, Toussaint *et al.* 2006, Veronesi *et al.* 2005).

Although not confirmed by laboratory assays, BT has been suspected in some regions of the Middle East since the 1920s (Shimshony 2004).

Epizootic haemorrhagic disease virus

Infection by the EHDV was first reported in wild ruminants (deer) in New Jersey, USA during August 1955, by Shope and colleagues (Shope *et al.* 1955, Shope *et al.* 1960), and subsequently it was

presented as blackleg or mycotic stomatitis, and black tongue or haemorrhagic septicaemia became the first main clinical description of EHDV infection in cattle. The disease was termed EHD because of the wide spatial distribution of outbreaks in the USA and Canada (Shope *et al.* 1955, Shope *et al.* 1960). From August through December 1959, a similar disease, characterized by fever and stomatitis in cattle, occurred in Japan (Inaba 1975, Inaba *et al.* 1966). It was eventually called “Ibaraki disease” (Goto 1959), but some authors called it “bluetongue-like” disease (Inaba *et al.* 1966, Nara-Pereira *et al.* 2000, Omori 1961, Omori *et al.* 1969 a, b).

Indeed, some clinical manifestations of EHD are similar to those caused by BTV, including oedema of the conjunctiva, udder, oral, and nasal mucous membranes, and muzzle (Brenner 2010, Radostits *et al.* 2007, Yadin *et al.* 2007, Yadin *et al.* 2008). The generic name “haemorrhagic diseases” has been adopted, to encompass BT, ID and EHD. In some cases of ID or EHD, erosions and/or ulcerations develop at the coronary band, causing lameness, at the same time the tongue can swallow, resembling the characteristic clinical signs of BT in sheep.

Orbiviral infections in domestic ruminants in Israel

The first indications of haemorrhagic viral diseases in domestic ruminants in Israel came from field observations carried out by Komarov and Goldsmith (Komarov and Goldsmith 1951), who reported on an outbreak similar to BT. However, no confirmatory laboratory test was then available to ascertain whether the circulating viruses were BTV or EDHV. Previously, several tentative or small-scale serological surveys had been carried out in Israel, to evaluate observations made by field practitioners regarding the appearance of sporadic cases of haemorrhagic disease in cattle. Although, it had initially been suggested that these might be ID, the results were inconclusive (Brenner unpublished data, personal communication). Some of the information gaps regarding orbiviral infections between 2006 and 2008 have been summarized by Brenner (Brenner 2009).

BTV infection in domestic ruminants in Israel until 2006

The most comprehensive history of BT in Israel up to 2004 has been presented by Shimshony (Shimshony 2004). No substantial variations were noted until 2006, when the appearance of BTV-15, for the first time in the region, caused considerable mortality (about 50%) in a single sheep flock, but not in dairy cows present in the same premises (Brenner 2009, Yadin *et al.* 2007, Yadin *et al.* 2008).

The history of the characteristic BT situation in Israel up to 2004 can be summarized as follows (Shimshony 2004):

- a. Bluetongue virus appears each year, from July through December throughout Israel, except in the Southern Arava;
- b. although BT may have been observed in cattle, such cases seem to have been extremely rare, involving 6- to 12-month-old dairy animals, which presented very mild symptoms (elevated temperature, hyperaemia with slight necrosis of the oral papillae, coronitis);
- c. five serotypes of BTV were identified in Israel (first year of identification in brackets): BTV-4 (1950), BTV-10 (1965), BTV-16 (1966), BTV-6 (1972), and BTV-2 (1973);
- d. since 1973, no new serotypes have been added to the list;
- e. the most prevalent was BTV-4. Typically, in most years only 1 serotype was identified in clinically affected sheep;
- f. Bluetongue virus infection has never been correlated with fertility problems in Israeli cattle (Barzilai *et al.* 1975);
- g. no infected swarms of *Culicoides imicola* have been found in mountains in Israel higher than 500 m [extrapolation from (Shimshony 1980)].

EHDV infection in domestic ruminants in Israel until 2006

As mentioned above, Komarov and Goldsmith (Komarov and Goldsmith 1951) reported a disease outbreak similar to BT in Israel but no confirmatory laboratory tests were available to ascertain whether the circulating viruses were BTV or EDHV. However, haemorrhagic symptoms in cattle appeared sporadically in such a characteristic manner that led some field practitioners to suspect that ID was present in Israel. The ID virus is classified as EHDV serotype 2 (MacLachlan and Osburn 2004). More recently several tentative or small-scale serological surveys were carried out to evaluate observations made by field practitioners regarding the appearance of sporadic cases of haemorrhagic diseases and, although it had initially been suggested that these might be ID, the results were inconclusive (Brenner unpublished data).

BT and BTV in Israel from 2006 to date

Since 2006, 8 BTV serotypes (BTV-2, BTV-4, BTV-5, BTV-8, BTV-12, BTV-15, BTV-16, and BTV-24) have been identified circulating in diseased sheep and cattle in Israel. The clinical manifestations are

generally similar to those already attributed to BTV infection in cattle in Europe (Campbell *et al.* 1978, Eschbaumer *et al.* 2010, Jeggo *et al.* 1987, Muller-Doblies *et al.* 2007, Pardon *et al.* 2010, Thiry *et al.* 2006, Toussaint *et al.* 2006, Veronesi *et al.* 2005). However, these studies describe clinical signs associated with a single BTV strain (BTV-8), whereas the clinical signs described in cattle in Israel during the 8 years since 2006 indicate a “cluster” of signs caused by multiple co-circulating serotypes of BTV (Brenner *et al.* 2010, Brenner *et al.* 2011).

These clinical manifestations have been categorized as a syndrome. The 6 clinical syndromes that have been described in dairy cattle in Israel are: “footrot-like syndrome”, “sore nose syndrome”, “subcutaneous emphysema syndrome”, “red/rough udder syndrome”, “BT/EHD systemic syndrome”, and “maladjustment syndrome” (Brenner *et al.* 2010, Brenner *et al.* 2011). Two episodes of abortion/hypofertility in 2 dairy cattle farms in 2010 were connected with BTV-12: 1 herd reported 88 “empty” heifers; the other suffered 50% of “empty” lactating cows (Bluetongue, bovine, Israel: BTV-12 2010, O.I.E. 20111006.3005). Two additional outbreaks of respiratory distress – acute post-BT pleuro-pneumonia – have been connected with BTV-4 in 2 adjacent large dairy cattle farms (Brenner personal communication).

Interestingly, the clinical similarity between BT and EHD is better expressed the BT/EHD systemic syndrome (Brenner *et al.* 2011), which was initially suspected to be EHDV infection and later found to be BT, caused by BTV serotype 24 (Brenner 2010). In addition several BTV serotypes have been associated with disease in goats in Israel (Bumbarov *et al.* 2012).

EHD and EHDV in Israel from 2006 to date

Towards the end of August 2006, an unidentified haemorrhagic outbreak was noticed in several dairy cattle farms in the Southern Jordan River Valley in Israel (Kedmi *et al.* 2011, Yadin *et al.* 2007, Yadin *et al.* 2008). Beside the nonspecific manifestations, the characteristic clinical signs, including petechial lesions on the tips of the lingual and buccal papillae (Yadin *et al.* 2007, Yadin *et al.* 2008), were similar to those noted in several other haemorrhagic syndromes in ruminants (Radostits *et al.* 2007). Additional clinical signs included prominent serous to purulent nasal discharge, excessive salivation, and nasal and lip redness, with scaling and tongue swelling, cyanosis, and erosions. Some animals showed ocular signs of epiphora, conjunctival hyperaemia, and submandibular, and palpebral oedema. Several animals exhibited red to purple discoloration of the udder, and hoof oedema with echymotic haemorrhages. However, not all of these

clinical signs were seen on any one farm; the first signs included a sharp drop in milk production, which was accompanied by weight loss and loss of appetite.

The duration of the disease in individual animals was reported to range between 3 and 30 days. The presence of EHDV in samples collected at the onset of the outbreak was confirmed by using a virus-/species-/serogroup-specific reverse transcriptase polymerase chain reaction (RT-PCR) targeting genome segment 7 (Maan et al. 2007, Maan et al. 2010, Mertens et al. 2007).

After cessation of clinical manifestations in Israel, it was possible to ascertain that the spatial distribution (Kedmi et al. 2011) was similar to those noted during previous outbreaks of BT and arthrogryposis hydranencephaly syndrome (AHS) (related to infection with the Simbu serogroup viruses) in Israel (Brenner 2009, Brenner 2010, Brenner et al., 2004 a, b, c, Brenner et al. 2011, Markusfeld-Nir and Mayer 1971, Yadin et al. 2007, Yadin et al. 2008). This spreading of clinical appearances suggested that a vector, *C. imicola*, was responsible for these outbreaks (Mellor and Wittman 2002, Mellor et al. 2000). There were no reports of a distinctive disease syndrome in sheep or goats in these areas during that time.

The clinical similarity between BT and EHD is especially expressed in the BT/EHD systemic syndrome. Indeed, this syndrome was initially suspected to be related to EHDV infection, but later it was found to be 1 of the clinical features of BTV-24 infection in dairy cattle (Brenner 2010, Brenner et al. 2010).

Although several dozen EHDV-PCR assays have been performed every year since 2006, no positive reactions have been detected, but there has been some serological evidence of the probable circulation of the virus in cattle older than 8 months, that were born after 2009 or 2010 (Brenner unpublished data). While preparing this publication, EHDV-6 was isolated from several clinical cases in 2016 (Bumbarov, personal communication, unpublished data).

Changes and peculiarities in orbiviral haemorrhagic disease in Israel since 2006

Bluetongue has appeared each year, from January to December (Table I, Figures 1-4). Moreover, there have been peaks of activity from January to March (Figures 2-4) – months that previously had been quiescent (Shimshony 2004).

The appearance of clinical BT/EHD (and AHS)

Table I. Bluetongue virus serotypes in Israel from 2009 to 2014: the serotyping was done by serotype-specific real-time polymerase chain reaction.

Year	Bluetongue virus- Serotype (number of identifications)									Total positive/number of samples (%)
	BTV-2 (n)	BTV-4 (n)	BTV-5 (n)	BTV-8 (n)	BTV-12 (n)	BTV-15 (n)	BTV-16 (n)	BTV-24 (n)	Inc**	
2009		5	2	3	0	0	3	10	12	
2010	3	5	0	22	2	2	0	6	258	298/1,379 (21.6%)
2011	6	6	1	0	1	0	2	0	61	77/706 (10.95%)
2012	35	14	0	0	0	0	2	0	176	227/1,027 (22.1%)
2013	1	7	0	0	0	0	7	0	132	147/726 (20.2%)

*To date only; ** Inconclusive.

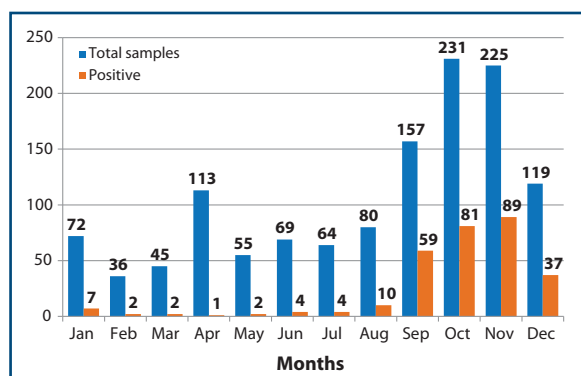


Figure 1. Total number of samples tested for Bluetongue virus and number of positive reactions in Israel, in 2010.

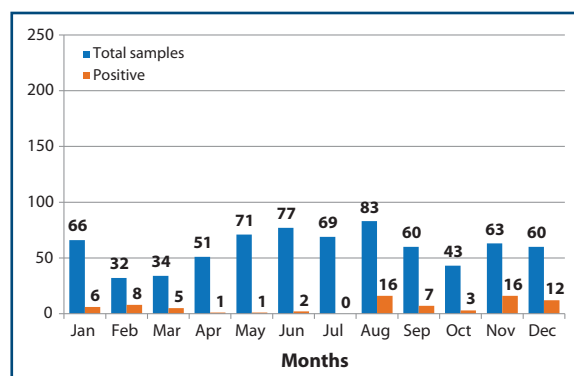


Figure 2. Total number of samples tested for Bluetongue virus and number of positive reactions in Israel, in 2011.

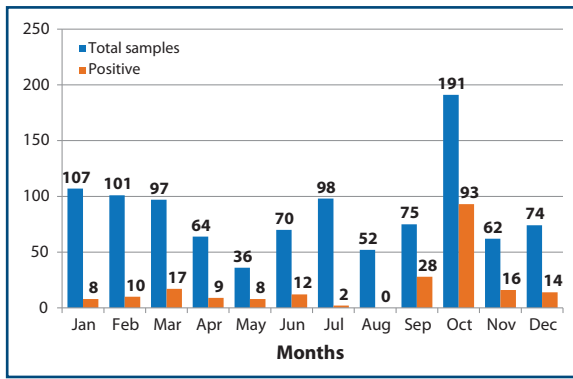


Figure 3. Total number of samples tested for Bluetongue virus and number of positive reactions in Israel, in 2012.

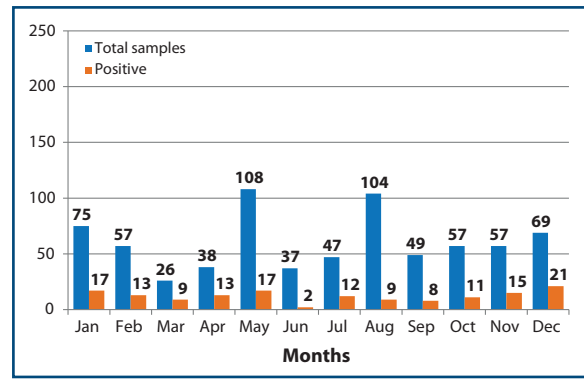


Figure 4. Total number of samples tested for Bluetongue virus and number of positive reactions in Israel, in 2013.

has demonstrated that the spatial distribution of competent vectors has broadened (Brenner 2009, Brenner 2010, Brenner *et al.* 2004c, Brenner *et al.* 2011) and the disease has appeared even in arid zones, such as the Southern Arava, which was considered free from blood-sucking vectors until 2006 (Markusfeld-Nir and Mayer 1971, Shimshony 1980, Shimshony 2004) (Figures 5 and 6).

The same changes occurred regarding the topographical distribution of the vectors: no altitude limits have been encountered, and BT appeared in cattle even on the Golan Heights, above 700 m (Figures 5-8).

Additional BTV serotypes have been found circulating in Israel – BTV-5, BTV-12, BTV-15, BTV-8, and BTV-24 (Brenner *et al.* 2010, Brenner *et al.* 2011, Bumbarov *et al.* 2012) (Figures 5-8, Table I).

The clinical manifestations of infection in cattle have become more severe than described previously (Shimshony 2004) and have been documented and confirmed by novel, advanced laboratory assays. Importantly, these cases involved BTV infections (Brenner *et al.* 2011, Bumbarov *et al.* 2012) in adult cattle, whereas Shimshony reported only mild cases in yearlings (Shimshony 2004).

Dual- and triple-BTV infections, simultaneously

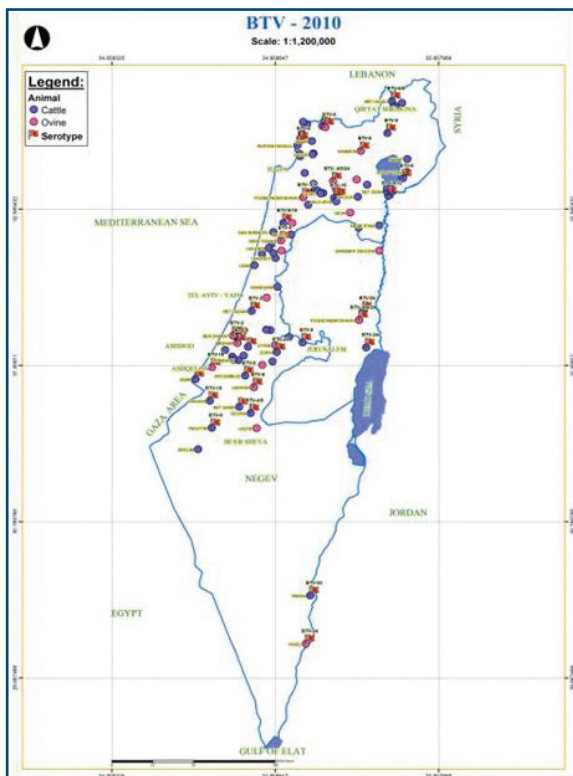


Figure 5. Bluetongue virus -affected sites in Israel, in 2010.

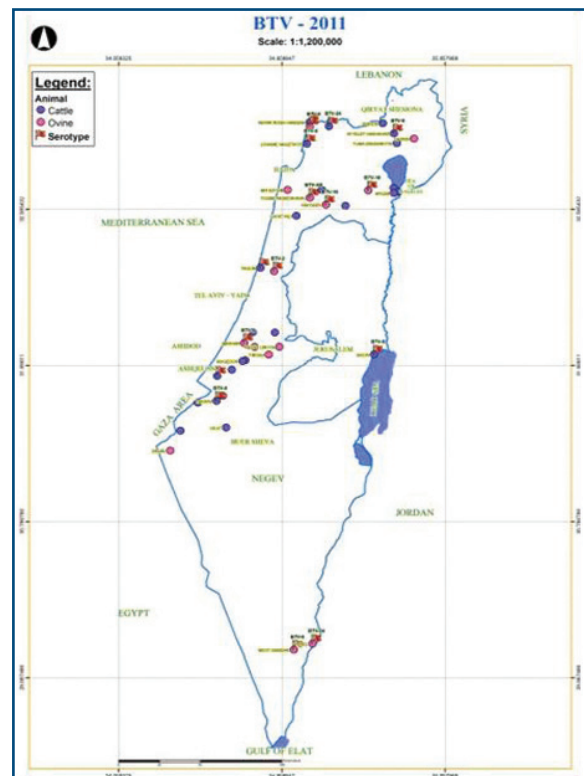


Figure 6. Bluetongue virus -affected sites in Israel, in 2011.

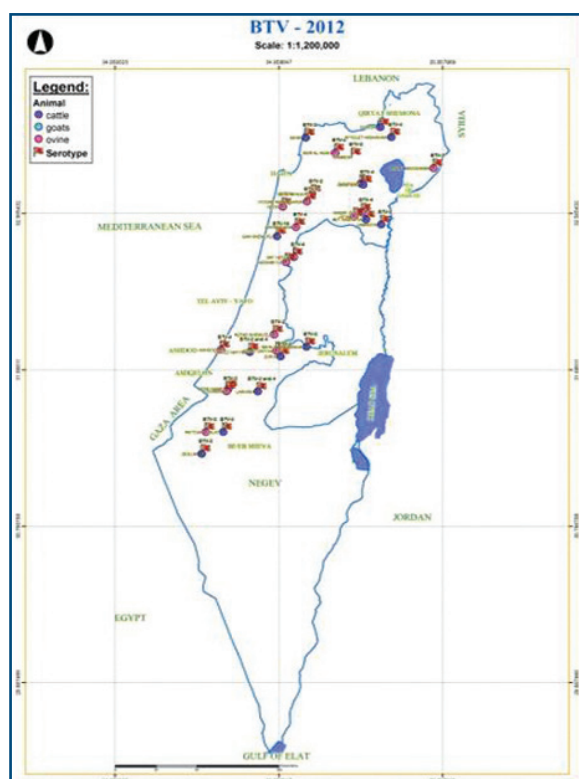


Figure 7. *Bluetongue virus -affected sites in Israel, in 2012.*

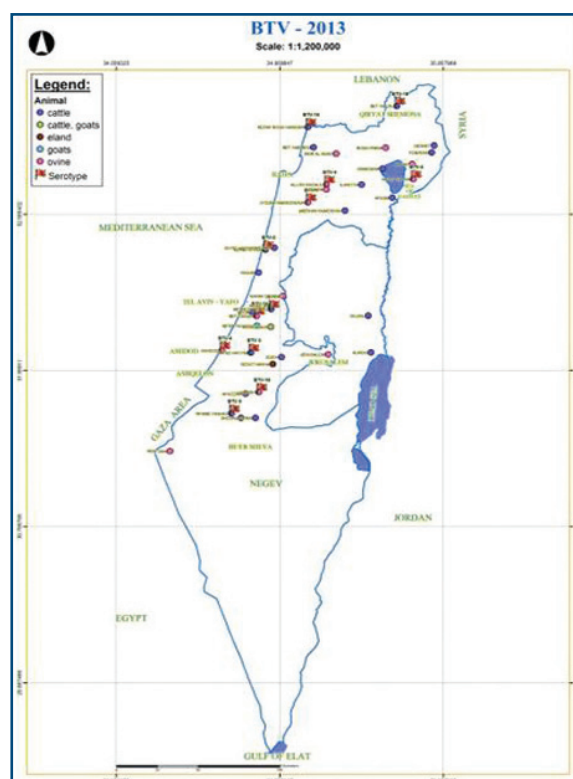


Figure 8. *Bluetongue virus -affected sites in Israel, in 2013.*

involving different BTV serotypes, have been documented, not only in the same infected site but, in several occasions, in the same animals (Brenner *et al.* 2004c, Brenner *et al.* 2011).

Serotype BTV-12 was associated with abortion storms in 2 dairy herds (Bluetongue, bovine, Israel: BTV-12 2010, O.I.E. 20111006.3005).

Clinical BT was documented in goats, in several cases that occurred during the 2009-2010 outbreaks (Bumbarov *et al.* 2012).

Similarities and differences between Israel and Europe reported during the orbiviral infections in farm ruminants

Awareness

The delayed response to the BTV-8 outbreak in Northern Europe occurred partly because BT had never previously been seen in that part of Europe, although it had been reported in sheep in other (Southern) European countries since the beginning of the new millennium (Schwartz-Cornil *et al.* 2008). Although Israeli practitioners were familiar with BT and BTV infections in sheep (Brenner *et al.* 2004a), they did not initially accept the possibility of cattle showing clinical signs that could be attributed to BTV infection. It seems that concepts rooted in the past

might act as obstacles to recognition of changes, and thus delay the dispatch of field information to the veterinary authorities.

Preparedness

The Israeli viral diagnostic laboratories realized that the diagnostic tools used prior to 2006 had not been adequate to cope with the new waves of activity of orbiviruses (BTV and EHDV) and their vectors (Brenner *et al.* 2004a). Therefore, initially, the Israelis were assisted by their European colleagues, who from 2000 onwards set up novel advanced diagnostic tools and established specialized arboviral laboratories. Moreover, the Europeans introduced novel concepts that have been only partially accepted by the Israeli practitioners and their veterinary authority.

Clinical manifestations

Generally speaking, there were no differences between the clinical manifestations documented in Israel and Europe (or elsewhere) (Brenner *et al.* 2011, Darpel *et al.* 2007, Eschbaumer *et al.* 2010, Jeggo *et al.* 1987, Muller-Doblies *et al.* 2007, Pardon *et al.* 2010, Temizel *et al.* 2009, Toussaint *et al.* 2006, Veronesi *et al.* 2005). However, the occurrence of a cluster of clinical syndromes has been documented only in Israel (Brenner *et al.* 2011). This could

be due to the unique climatic and topographic micro-environments that exist in this country, and which might serve as biological 'laboratories' (hotbeds) promoting the evolution of arboviruses.

The European investigators were the first to realize that cattle might suffer from BT attributed to BTV infection, and thus facilitated the Israelis' acceptance of European notions regarding this controversial issue. At the same time, the Israelis were the first to ascertain that the "Mediterranean" EHDV, in accordance with the Japanese ID (Goto 1959, Inaba 1975, Inaba *et al.* 1966, Omori 1961, Omori *et al.* 1969 a, b) could cause considerable damage to the industrialized dairy cattle farms as well (Brenner *et al.* 2010, Kedmi *et al.* 2010, Thiry *et al.* 2006, Yadin *et al.* 2007, Yadin *et al.* 2008). It should also be noted that Europe, apart from Turkey, seems to be free from EHDV infection.

Epidemiology

Changes in BTV serotypes, namely, the appearance or disappearance of certain BTV serotypes between 2009 and 2014, occurred at the international level without being affected by any statutory measures, such as mass vaccination, restriction of movement, etc. The BTV serotypes that persist in Israel for long periods seem to be BTV-2, BTV-4, and BTV-16, whereas other serotypes 'come and go'. For instance, BTV-15 appeared in

2006 and subsequently only in 2010, after which it disappeared again. Moreover, surprisingly, BTV-8 has not been identified in Israel since 2010. However, while preparing this manuscript, BTV-8 was isolate again in Israel in 2015 (Bumbarov, personal communication, unpublished data).

Control/eradication

It was only during 2012 that the Israeli artificial insemination centre adopted a protocol intended to prevent BTV spreading via artificial insemination. This Israeli lack of procedures was completely contrary to the European practices, such as mass vaccinations and restriction of animal movements. Therefore, the epidemiological changes noted in Israel cannot be designated as iatrogenic and/or caused by 'preventive' interventions. The most important controversial fact concerning the BTV-8 issue is that, while the Europeans claimed to have eradicated this particular serotype by using vaccines (Oura *et al.* 2009, Pardon *et al.* 2010, Schwarts-Cornil *et al.* 2008), Israel did nothing to this end.

Although there has been re-evaluation during the recent decade, the orbivirus situation in Israel requires better clarification, in order to understand orbiviral biology and epidemiology, and how the orbiviruses interact with their blood-sucking vectors and their ruminant hosts.

References

- Barzilai E., Bar-Tana U., Choen R., Eyal Y., Shimshony A. & Trainin Z. 1975. Natural infection of pregnant cattle with the virus of bluetongue: the effect on their progeny. *Refuah Vet*, **32**, 1-6.
- Brenner J. 2009. Orbiviral diseases of ruminants in Israel 2006 to 2009. *Isr J Vet Med*, **64**, 88-90.
- Brenner J. 2010. Epizootic hemorrhagic disease *In Atlas of transboundary animal diseases*. (P.J. Fernández & W.R. White, eds). OIE, USDA, 75-81.
- Brenner J., Malkinson M. & Yadin H. 2004a. Application of various diagnostic procedures to epidemiological situations encountered during arboviral infection. *Vet Ital*, **40**, 567-571.
- Brenner J., Tsuda T., Yadin H. & Kato T. 2004b. Serological evidence for reactivity of Akabane virus in the northern valleys of Israel in 2001. *J Vet Med Sci*, **66**, 441-443.
- Brenner J., Yadin H., Chai D., Stram Y., Kato T. & Tsuda T. 2004c. Serological and clinical evidence for reactivity of arboviral teratogenic Simbu serogroup infection in Israel; 2001/2003. *Vet Ital*, **40**, 119-123.
- Brenner J., Oura C., Asis I., Maan S., Elad D., Maan N., Friedgut O., Nomikou K., Rotenberg D., Bumbarov V., Mertens P., Yadin H. & Carrie B. 2010. Multiple serotypes of bluetongue virus in sheep and cattle, Israel. *Emerg Infect Dis*, **16**, 2003-2004.
- Brenner J., Batten C., Yadin H., Rotenberg D., Bumbarov V., Friedgut O., Golender N. & Oura C.A. 2011. Clinical syndromes associated with the circulation of multiple serotypes of bluetongue virus in dairy cattle in Israel. *Vet Rec*, **169**, 389.
- Bumbarov V., Brenner J., Rotenberg D., Batten C., Sharir B., Gorohov A., Golender N., Shainin T., Kanigswald G., Asis I. & Oura C. 2012. The presence and possible effects of bluetongue virus in goat flocks in Israel. *Isr J Vet Med*, **67**, 237-244.
- Campbell C.H., Barber T.L. & Jochim M.M. 1978. Antigenic relationship of Ibaraki, bluetongue, and epizootic hemorrhagic viruses. *Vet Microbiol*, **3**, 15-22.
- Darpel K.E., Batten C., Veronese E., Shaw A., Anthony S., Bankowska K., Kgosana L., Bin-Tarif A., Carpenter C., Muller-Doblies U., Mellor P.S., Mertens P.P.C. & Oura C. 2007. Clinical signs and pathology shown by British sheep and cattle infected with bluetongue virus serotype 8 derived from the 2006 outbreak in northern Europe. *Vet Rec*, **161**, 253-261.
- Elbers A.R.W., Backx A., Ekker A.N., Van Der Spek P.A. & Van Rijn P.A. 2008a. Performance of clinical signs to detect bluetongue virus serotype 8 outbreaks in cattle and sheep during the 2006-epidemic in the Netherlands. *Vet Microbiol*, **129**, 156-162.
- Elbers A.R.W., Backx A., Meroc E., Gerbier G., Staubach C., Hendriks G., Van Der Spek A. & Mintiens K. 2008b. Field observations during the bluetongue serotype 8 epidemic in 2006. I. Detection of first outbreaks and clinical signs in sheep and cattle in Belgium, France and the Netherlands. *Prev Vet Med*, **87**, 21-30.
- Elbers A.R.W., Backx A., Mintiens K., Gerbier G., Staubach C., Hendriks G. & Van Der Spek A. 2008c. Field observations during the Bluetongue serotype 8 epidemic in 2006. II. Morbidity and mortality rate, case fatality and clinical recovery in sheep and cattle in the Netherlands. *Prev Vet Med*, **87**, 31-40.
- Elbers A.R.W., Van Der Spek A. & Van Rijn P.A. 2009. Epidemiologic characteristics of bluetongue virus serotype 8 laboratory-confirmed outbreaks in the Netherlands in 2007 and a comparison with the situation in 2006. *Prev Vet Med*, **92**, 1-8.
- Eschbaumer M., Hoffman B., Moss A., Savini G., Leone A., Koning P., Zemke J., Conraths F. & Beer M. 2010. Emergence of bluetongue virus serotype 6 in Europe – German field data and experimental infection of cattle. *Vet Microbiol*, **143**, 189-195.
- Foster N.M., Metcalf H.E., Barber T.L., Jones E.H. & Luedke A.J. 1980. Bluetongue and epizootic hemorrhagic disease virus isolations from vertebrate and invertebrate hosts at a common geographic site. *J Am Vet Med Ass*, **176**, 126-129.
- Goto M. 1959. Pathological studies of the so-called bovine influenza. I. On the changes in the visceral organs. *Jap J Vet Sci*, **21**, 123-129.
- Hofmann M.A., Renzullo S., Mader M., Chaignat V., Worwa G. & Thuer B. 2008. Genetic characterization of Toggenburg orbivirus, a new bluetongue virus, from goats, Switzerland. *Emerg Infect Dis*, **14**, 1855-1861.
- Inaba Y. 1975. Ibaraki disease and its relationship to bluetongue. *Aus Vet J*, **52**, 1978-1985.
- Inaba Y., Ishi S. & Omori T. 1966. Bluetongue-like disease in Japan. *Bul Off Int Epizoot*, **66**, 329-340.
- Jeggo M.J., Corteyn A.H., Taylor W.P., Davidson W.L. & Gorman B.M. 1987. Virulence of bluetongue virus for British sheep. *Res Vet Sci*, **42**, 24-28.
- Kedmi M., Van Straten M., Ezra E., Galon N. & Klement E. 2010. Assessment of the productivity effect associated with epizootic hemorrhagic disease in dairy herds. *J Dairy Sci*, **93**, 2486-2495.
- Kedmi M., Galon N., Herziger Y., Yadin H., Bombarov V., Batten C., Shpigel N.Y. & Klement E. 2011. Comparison of the epidemiology of epizootic haemorrhagic disease and bluetongue viruses in dairy cattle in Israel. *Vet J*, **190**, 77-83.
- Komarov A. & Goldsmith L. 1951. A disease similar to bluetongue in cattle and sheep in Israel. *Refuah Vet*, **8**, 69-74.
- Maan S., Maan N.S., Samuel A.R., Rao S., Attoui H. & Mertens P.P.C. 2007. Analysis and phylogenetic comparisons of full-length VP2 genes of the 24 bluetongue virus serotypes. *J Gen Virol*, **88**, 621-630.
- Maan S., Maan N.S., Van Rijn P.A., Van Gennip R.G., Sanders A., Wright I.M., Batten C., Hoffmann B., Oura C., Potgieter A.C., Nomikou K. & Mertens P. 2010. Full genome characterisation of bluetongue virus serotype 6 from the Netherlands 2008 and comparison to other field and vaccine strains. *PLoS One*, **5**, e10323.

- MacLachlan N.J. & Osburn B.B.I. 2004. Epizootic hemorrhagic disease of deer. *In* Infectious diseases of livestock, 2nd Ed. (J.A.W. Coetzer & R.C. Tustin, eds), Oxford University Press, Oxford, South Africa, 1227-1230.
- MacLachlan N.J., Drew C.P., Darpel K.E. & Worwa G. 2009. The pathology and pathogenesis of bluetongue. *J Comp Pathol*, **141**, 1-16.
- Markusfeld-Nir O. & Mayer E. 1971. An arthrogryposis/hydranencephaly syndrome in calves in Israel 1969/70 - epidemiological and clinical aspects. *Refuah Vet*, **28**, 144-151.
- Mellor P.S. & Wittman E.U. 2002. Bluetongue virus in the Mediterranean basin 1998-2001. *Vet J*, **164**, 20-37.
- Mellor P.S., Boorman J. & Balyis M. 2000. *Culicoides* biting midges: their role as arbovirus vectors. *Ann Rev Entomol*, **45**, 307-340.
- Mertens P.P.C., Maan N.S., Prasad G., Samuel A.R., Shaw A., Potgieter A.C., Anthony S.J. & Maan S. 2007. Design of primers and use of RT-PCR assays for typing European bluetongue virus isolates: differentiation of field and vaccine strains. *J Gen Virol*, **88**, 2811-2823.
- Muller-Doblies U., Mellor P.S., Mertenes P.P.C. & Oura C. 2007. Clinical signs and pathology shown by British sheep and cattle infected with bluetongue virus serotype 8 derived from the 2006 outbreak in northern Europe. *Vet Rec*, **161**, 253-261.
- Nara-Pereira E.M., Iwata H. & Inoue T. 2000. The complete nucleotide sequence of segment L2 of Ibaraki virus encoding for the antigen recognized by neutralizing antibodies. *J Vet Med Sci*, **62**, 317-321.
- Omori T. 1961. Bluetongue-like disease in Japan. *Bull Off Int Epizoot*, **55**, 1109-1117.
- Omori T., Inaba Y., Morimito T., Tanaka Y. & Ishitani R. 1969a. Ibaraki virus, an agent of epizootic disease of cattle resembling bluetongue. I. Epidemiologic, clinical and pathologic observations and experimental transmission to calves. *Jap J Microbiol*, **13**, 139-167.
- Omori T., Inaba Y., Morimito T., Tanaka Y. & Kono M. 1969b. Ibaraki virus, an agent of epizootic disease of cattle resembling bluetongue. II. Isolation of the virus in bovine cell culture. *Jap J Microbiol*, **13**, 159-168.
- Pardon B., Vandenberghe V., Maes S., De Clercq K., Ducatelle R. & Deprez P. 2010. Oesophageal paresis associated with bluetongue virus serotype 8 in cattle. *Vet Rec*, **167**, 579-581.
- Purse B.V., Mellor P.S., Rogers D.J., Samuel A.R., Mertenes P.P.C. & Baylis M. 2005. Climate change and the recent emergence of bluetongue in Europe. *Nature Rev Microbiol*, **3**, 171-181.
- Radostits O.M., Gay C.C., Blood D.C., Hinchcliff K.W. & Constable P.D. 2007. Hemorrhagic diseases. *In* Veterinary medicine. A textbook of the diseases of cattle, sheep, pigs, goats and horses. (O.M. Radostits, C.C. Gay, D.C. Blood, K.W. Hinchcliff & P.D. Constable, eds), W.B. Saunders, London, Edinburgh, New York, 1305.
- Roy P., French T. & Erasmus B.J. 1992. Protective efficacy of virus-like particles for bluetongue disease. *Vaccine*, **10**, 28-32.
- Schwartz-Cornil I., Mertens P.P., Conteras V., Hemati B., Pascale F., Brad E., Mellor P.S., MacLachlan N.J. & Zientara S. 2008. Bluetongue virus: virology, pathogenesis and immunity. *Vet Res*, **39**, 39-46.
- Shimshony A. 1980. An epizootic Akabane disease in bovines, ovines and caprines in Israel, 1969-70: epidemiological assessment. *Acta Morphol Acad Sci Hung*, **28**, 197-199.
- Shimshony A. 2004. Bluetongue in Israel - a brief historical overview. *Vet Ital*, **40**, 116-118.
- Shope E.R., Macnamara G. & Mangold R. 1955. Deer mortality - epizootic hemorrhagic disease of deer. *New Jersey Outdoor*, **6**, 17.
- Shope E.R., Lester M.D., Macnamara G. & Mangold R. 1960. A virus-induced epizootic hemorrhagic disease of the Virginia white-tailed deer (*Odocoileus virginianus*). *J Exp Med*, **111**, 155-170.
- Temizel E.M., Yestibag K., Batten C., Senturk S., Maan N.S., Mertenes P.P.C. & Batmaz H. 2009. Epizootic hemorrhagic disease in cattle, Western Turkey. *Emerg Infect Dis*, **15**, 317-319.
- Thiry E., Saegerman C., Guyot H., Kirten P, Losson B., Rollin F., Czaplicki G., Toussaint J-F., De Clercq K., Dochy J-M., Dufey J., Gillema J.L. & Messemann K. 2006. Bluetongue in northern Europe. *Vet Rec*, **159**, 327.
- Toussaint J-F., Vandenbusche F., Mast J., De Meester L., Goris N., Van Dessel W., Vanopdenbosche P, Kerkhofs P, De Clercq K., Zientara S., Sailleau C., Czaplicki G., Depooter G. & Dochy J.M. 2006. Bluetongue in northern Europe. *Vet Rec*, **159**, 327.
- Veronesi E., Hamblin C. & Mellor P.S. 2005. Live attenuated bluetongue vaccine viruses in Dorset Poll sheep, before and after passage in vector midges (Diptera: Ceratopogonidae). *Vaccine*, **23**, 5509-5516.
- Yadin H., Brenner J., Gelman B., Bumbarov V., Stram Y., Oved Z., Galon N. & Klement E. 2007. A large-scale outbreak of bovine hemorrhagic disease in Israel. *Isr J Vet Med*, **62**, 28-29.
- Yadin H., Brenner J., Bumbarov V., Oved Z., Stram Y., Klement E., Perl S., Antony S., Maan S., Batten C. & Mertens P.P.C. 2008. Epizootic haemorrhagic disease virus type 7 infection in cattle in Israel. *Vet Rec*, **162**, 53-56.