

# Canine testicular tumours: a retrospective investigation in Abruzzo and Molise, Italy

Anna Rita D'Angelo, Serafina Vita, Giuseppe Marruchella & Gabriella Di Francesco

## Summary

Canine testicular tumours frequently occur and share relevant features with their human counterparts, thus being a putative model in comparative oncology. The authors present data on canine testicular tumours submitted to the *Istituto G. Caporale* over the last 12 years. In total, 183 testicular neoplasms were diagnosed: 108 seminomas, 37 Sertoli cell tumours, 18 interstitial Leydig cell tumours, 10 mixed tumours, 9 other primary tumours and one metastatic neoplasm. A systematic and more detailed collection of data (signalling, history, clinical signs and follow-up) enables a better evaluation of clinical and biological features of animal tumours, as well as a clear assessment of the real impact, if any, of specific intrinsic and extrinsic risk factors.

## Keywords

Abruzzo, Comparative pathology, Dog, Italy, Molise, Pathology, Testis, Tumour.

## Introduction

Primary testicular tumours are commonly observed in dogs and less frequently in other animal species. On the basis of the neoplastic cell type, testicular tumours are usually classified as follows:

- germ cell tumours (seminoma)
- sex cord-stromal tumours (Sertoli cell tumour and interstitial Leydig cell tumours)
- mixed germ cell/sex stromal cell tumours.

Additional testicular tumours from different cell lineages are also reported occasionally (10, 20).

Seminoma (SEM) consists of 'diffuse' or 'intra-tubular' proliferating cells, which are usually large, sometimes multinucleated, and round, ovoidal or polygonal in shape. Mitoses, as well as haemorrhages, necrosis and lymphocytic aggregates are commonly detected (Fig. 1). Despite such apparently malignant features, canine SEM rarely metastasises, affecting one or more lymph nodes (3, 4, 5, 10, 20). Sertoli

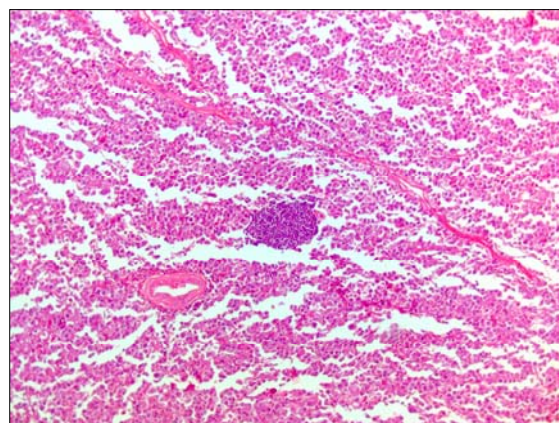


Figure 1  
Dog testis: seminoma  
A typical lymphoid nodule is seen within the neoplastic tissue  
Haematoxylin-eosin (×10)

cells play a key role in spermatogenesis by providing structural and trophic support to germ cells and contributing to their immune segregation (9). Microscopically, Sertoli cell tumours (SCTs) consist of intra-tubular or diffuse layers of elongated cells (Fig. 2). Mitoses and metastases are rare. SCTs can produce oestrogen and cause a paraneoplastic

Diagnostic Microbiology, Pathology, Parasitology and Mycology Unit, Istituto G. Caporale, via Campo Boario, 64100 Teramo, Italy  
a.dangelo@izs.it, g.difrancesco@izs.it

syndrome characterised by feminisation (10, 19, 20).

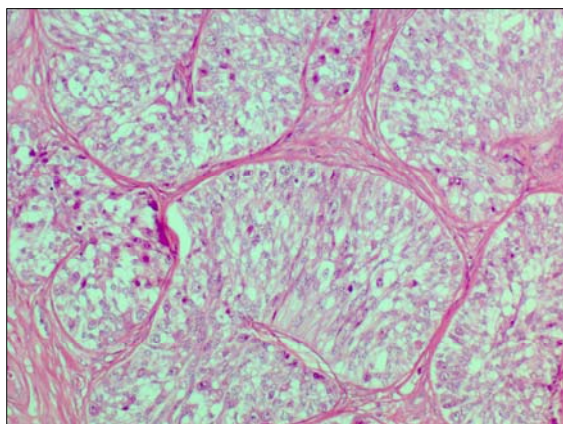


Figure 2  
Dog testis: Sertoli cell tumour  
Neoplastic cells are spindle-shaped, with indistinct  
borders and arranged as palisades  
Haematoxylin-eosin (×40)

Leydig cells are the main source of androgens and reside within the interstitium, in intimate connection with blood vessels and seminiferous tubules (2). Leydig cell tumours (LCTs) consist of polygonal, cubic, or cylindrical cells, with a strongly eosinophilic cytoplasm which sometimes contains pigments and/or lipidic vacuolation. Microscopically, three different histopathological patterns can be observed, which often co-exist within the same lesion, as follows:

- solid-diffuse
- cystic-vascular
- pseudoadenomatous (Fig. 3).

Mitoses and metastases are rare. LCTs may produce steroids, thus causing a paraneoplastic syndrome characterised by hyperandrogenism (10, 20).

In dogs, the simultaneous presence of germ cell and sex stromal cell tumours frequently occurs. The association SEM/SCT appears to be the most frequent, but SEM/LCT, SCT/LCT and SEM/SCT/LCT have also been reported (5, 10, 12, 15, 20).

A number of intrinsic (e.g. breed) and extrinsic factors (e.g. environmental pollutants) have been thought to contribute to the development of testicular tumours in dogs. A growing body of evidence suggests that the risk of

developing testicular neoplasms significantly increases with age (10, 12, 20) and in cryptorchid subjects (7, 10, 12, 17, 20).

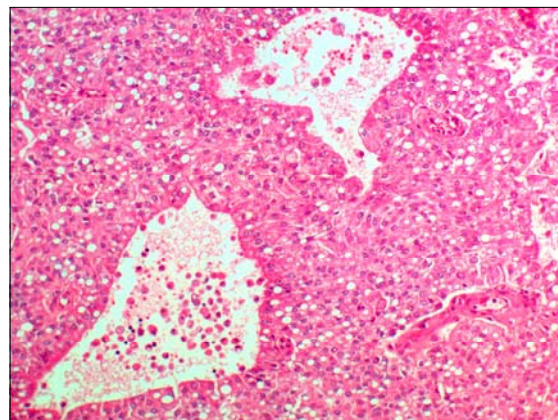


Figure 3  
Dog testis: Leydig cell tumour  
The cytoplasm of neoplastic cells appears typically  
vacuolated  
Haematoxylin-eosin (×20)

Here, we provide data on testicular neoplasia submitted to the *Istituto G. Caporale* over the past 12 years, in an attempt to provide a greater insight in this field of veterinary oncology.

## Materials and methods

All samples that we investigated were submitted to the *Istituto G. Caporale* by veterinary practitioners working in the Abruzzo and Molise Regions. Tissue samples were collected during routine castration, orchiectomy or bioptic sampling. Specimens were fixed in 10% neutral buffered formalin, embedded in paraffin, and 5 µm-thick sections were cut and stained with haematoxylin and eosin. Tumours were classified according to the guidelines proposed by the World Health Organization (10). Whenever possible, data on breed, age, cryptorchidism and clinical signs (including the presence of paraneoplastic syndromes) were collected.

## Results

In total, 183 testicular tumours were diagnosed, as follows:

- 108 SEM (59%)

- 37 SCTs (20.2%)
- 18 LCTs (9.8%)
- 10 mixed tumours (5.4%)
- 9 different 'miscellaneous' tumours (4.9%)
- 1 metastatic lesion (0.5%).

Age information was available for 21 dogs, where age ranged from 6 to 17 years (mean age: 11.9 years). Breed was known for 23 dogs, as follows: mongrels (9), Pinscher (9), German Shepherd (2), Yorkshire, Siberian Husky, Bracco, Beagle, Poodle, Irish Setter, English Setter, Rottweiler, Abruzzese and Pomeranian.

A total of 25 tumours (13.6%) were detected in cryptorchid dogs (17 SEMs and 8 SCTs). Mixed germ cell/sex stromal cell tumours were represented as follows:

- 6 SEM/SCT
- 3 SEM/LCT
- 1 SEM/SCT/LCT.

The last subject showed a mixed SEM/SCT tumour in one testis, whereas LCT affected the contralateral one; cryptorchidism was not present.

History indicated the simultaneous presence of perianal gland adenoma in 3 dogs (1 SEM, 1 LCT, 1 SEM/LCT) and prostatic hypertrophy in 4 dogs (2 SEM, 1 SCT, 1 LCT). Furthermore, symmetric alopecia was reported in 3 subjects (1 SEM, 1 SCT, 1 SEM/SCT), while only one dog developed the feminisation syndrome by hyperestrogenism (SEM/SCT).

A total of 9 primary tumours were also reported from different cell types, as follows:

- 3 hemangiomas
- 5 hemangiosarcomas
- 1 lipoma.

Finally, a scrotal mast cell tumour metastasised within the testicular parenchyma in one subject.

## Discussion

Neoplastic disorders have been gaining relevance in veterinary medicine and represent a continuous challenge for veterinarians. In addition, pet animals share the environment with their human companions, thus being exposed to the same hazards. Therefore, pets may serve as useful environmental 'sentinels'

of cancer risks. This adds further value to the study of naturally occurring neoplasms in domestic animals which can provide a useful (sometimes irreplaceable) contribution in comparative oncology (8, 16, 18).

In this respect, we draw attention to the fact that canine SEMs share some biological and histopathological features with their human counterparts and this may represent a valuable tool for studying human cancer (1, 11).

Nevertheless, it is always difficult to estimate the true incidence, as well as the biological pattern and clinical outcome, of spontaneous tumours in domestic animals. Data reported here confirm that testicular tumours are common in dogs and represent about 5% of all canine neoplasms diagnosed during the same study period at the *Istituto G. Caporale*. In particular, in agreement with previous reports (6), testicular neoplasia accounts for about 90% of all tumours affecting male genitalia. However, such data must be interpreted with caution since clinical signs (increased testicular size, scrotal swelling, cryptorchidism, symmetric alopecia, hyperestrogenism) are easily recognised by owners and veterinarians encourage further diagnostic investigations (13). In addition, the common practice of neutering male dogs can lead to the diagnosis of discrete, otherwise unidentified, lesions.

Data on the relative rate – expressed as a percentage – of canine testicular tumours vary greatly (5, 6, 12) and differ from those reported here. It seems worthwhile to draw attention to the sampling procedure which has a significant impact on such data. For example, LCTs are often detected in 'normal' testes collected from 'healthy' animals (>50% according to Liao *et al.* [12]). Consequently, LCT percentages can appear to be low whenever investigation includes only – or almost exclusively – macroscopically detectable lesions collected from dogs with obvious clinical signs.

The incidence of tumours metastatic to the testis is unknown and is presumably very low (10). Therefore, our report of a single testicular metastasis is not surprising. Primary non-SEM/non-SCT/non-LCT testicular tumours,



including those from tunica vaginalis, also occur rarely in animals and human beings (10, 22). Interestingly, a relatively high number of primary tumours arising from vasculature have been reported here and will be investigated further.

The mean age of dogs included in the present investigation was high, thus confirming the fact that old dogs have a higher risk of testicular cancer (6, 10, 12, 20). It has been suggested that certain canine breeds (mainly small or toy size) have an increased risk of developing testicular tumours, probably because of a higher risk of cryptorchidism. In our study, no breed effect appeared to exist, although our small amount of data does not enable a reliable assessment to be made of that suggested risk factor. However, the composition of the canine population – which largely varies depending on the geographic areas – can also bias such data (5, 7, 12, 17).

Valuable 'quali-quantitative' data on canine populations and the systematic reporting of their tumours are a fundamental pre-requisite

for the reliable assessment of the incidence of neoplastic diseases, as well as the impact of specific risk factors (13, 21). Approximately 80 000 dogs are registered in the Abruzzo and Molise Regions (14); however, such data are presumably inaccurate and have been underestimated, thus biasing epidemiological studies for veterinary oncology purposes.

## Conclusions

The present study which provides information on a series of canine testicular tumours represents a useful source of information in the fields of canine and comparative oncology. In the near future, an extensive and more detailed collection of data is needed, to ensure that clinical and biological features of such tumours are reliable and accessible, as well to carefully consider the load of specific risk factors.

## References

1. Bush J.M., Gardiner D.W., Palmer J.S., Rajpert-De Meyts E. & Veeramachaneni D.N.R. 2011. Testicular germ cell tumours in dogs are predominantly of spermatocytic seminoma type and are frequently associated with somatic cell tumours. *Int J Androl*, **34**, 288-295.
2. Ge R., Chen G. & Hardy M.P. 2008. The role of the Leydig cell in spermatogenic function. *Adv Exp Med Biol*, **636**, 255-269.
3. Grieco V., Rondena M., Romussi S., Stefanello D. & Finazzi M. 2004. Immunohistochemical characterization of the leucocytic infiltrate associated with canine seminomas. *J Comp Pathol*, **130** (4), 278-284.
4. Grieco V., Riccardi E., Rondena M., Ciampi V. & Finazzi M. 2007. Classical and spermatocytic seminoma in the dog: histochemical and immunohistochemical findings. *J Comp Pathol*, **137** (1), 41-46.
5. Grieco V., Riccardi E., Greppi G.F., Teruzzi F., Iermanò V. & Finazzi M. 2008. Canine testicular tumours: a study on 232 dogs. *J Comp Pathol*, **138** (2-3), 86-89.
6. Hayes H.M. & Pendergrass T.W. 1976. Canine testicular tumors: epidemiologic features of 410 dogs. *Int J Cancer*, **18** (4), 482-487.
7. Hayes H.M., Wilson G.P., Pendergrass T.W. & Cox V.S. 1985. Canine cryptorchism and subsequent testicular neoplasia: case-control study with epidemiologic update. *Teratology*, **32** (1), 51-56.
8. Hayes H.M., Tarone R.E., Casey H.W. & Huxsoll D.L. 1990. Excess of seminomas observed in Vietnam service US military working dogs. *J Natl Cancer Inst*, **82** (12), 1042-1046.
9. Johnson L., Thompson D.L. & Varner D.D. 2008. Role of Sertoli cell number and function on regulation of spermatogenesis. *Anim Reprod Sci*, **105** (1-2), 23-51.
10. Kennedy P., Cullen J.M., Edwards J.F., Goldschmidt M.H., Larsen S., Munson L. & Nielsen S. 1998. Histological classification of tumors of the genital system of domestic animals. In World Health Organization international histological classification of tumors of domestic animals, Vol. IV. Armed Forces Institute of Pathology, Washington, DC, 17-18.

11. Kim J.K., Yu C.H., Yhee J.Y., Im K.S., Kim N.H. & Sur J.H. 2010. Classical seminoma: a specific malignant type with human classifications is highly correlated with tumor angiogenesis. *BMC Cancer*, **10**, 243.
12. Liao A.T., Chu P.Y., Yeh L.S., Lin C.T. & Liu C.H. 2009. A 12-year retrospective study of canine testicular tumors. *J Vet Med Sci*, **71** (7), 919-923.
13. Merlo D.F., Rossi L., Pellegrino C., Ceppi M., Cardellino U., Capurro C., Ratto A., Sambucco P.L., Sestito V., Tanara G. & Bocchini V. 2008. Cancer incidence in pet dogs: findings of the animal tumor registry of Genoa, Italy. *J Vet Intern Med*, **22**, 967-984.
14. Ministero della Salute 2012. Banca dati dell'Anagrafe Animali d'Affezione. Ministero della Salute, Rome ([www.salute.gov.it/anagcaninapublic\\_new/home.jsp](http://www.salute.gov.it/anagcaninapublic_new/home.jsp) accessed on 15 August 2012).
15. Patnaik A.K. & Mostofi F.K. 1993. A clinicopathologic, histologic, and immunohistochemical study of mixed germ cell-stromal tumors of the testis in 16 dogs. *Vet Pathol*, **30** (3), 287-295.
16. Pinho S.S., Carvalho S., Cabral J., Reis C.A. & Gärtner F. 2012. Canine tumors: a spontaneous animal model of human carcinogenesis. *Transl Res*, **159** (3), 165-172.
17. Reif J.S. 1979. A cohort study of canine testicular neoplasia. *Vet Clin North Am Large Anim Pract*, **1** (1), 3-15.
18. Reif J.S. 2011. Animal sentinels for environmental and public health. *Public Health Rep*, Suppl. 1, 50-57 ([www.ncbi.nlm.nih.gov/pmc/articles/PMC3072903/](http://www.ncbi.nlm.nih.gov/pmc/articles/PMC3072903/) accessed on 19 August 2012).
19. Turek M.M. 2003. Cutaneous paraneoplastic syndromes in dogs and cats: a review of the literature. *Vet Dermatol*, **14**, 279-296.
20. Valenza F. 1997. Classificazione e caratteristiche morfologiche dei tumori dell'apparato genitale maschile nei mammiferi domestici. In *Diagnostica Istologica dei Tumori degli Animali*. Fondazione Iniziative Zooprofilattiche e Zootecniche, Brescia, 273-282.
21. Vascellari M., Baioni E., Ru G., Carminato A. & Mutinelli F. 2009. Animal tumour registry of two provinces in northern Italy: incidence of spontaneous tumours in dogs and cats. *BMC Vet Res*, **5** (39), doi:10.1186/1746-6148-5-39.
22. Vascellari M., Carminato A., Camali G., Melchioni E. & Mutinelli F. 2011. Malignant mesothelioma of the tunica vaginalis testis in a dog: histological and immunohistochemical characterization. *J Vet Diagn Invest*, **23**, 135-139.