

Determination of first pregnancy and foetal measurements in Egyptian Baladi goats (*Capra hircus*)

Hussein A. Amer

Summary

This study was conducted using B-mode transrectal (TR) and transabdominal (TA) ultrasonography to determine early pregnancy and fetometry. A total of 110 does aged between 8 and 36 months were used. The detection of early pregnancy and foetal number was measured. The relationship between gestation age and crown-rump length (CRL) and bi-parietal diameter (BPD) was determined from days 40 to 109 of gestation. The accuracy of foetal sexing was determined by differentiation of genital tubercle (GT) from days 40 to 109 of gestation and then followed up after birth. The examination revealed 95.5% of does were pregnant, with 100% accuracy in detecting pregnancy for positive cases. The foetal number was 45.7% and 54.3% for single and twins/triplets. The TR probe enabled more reliable and early recognition of foetal fluid (5 days) and heart beats (4 days) than the TA probe. The TR observation of heart beats is recommended as conclusive evidence of the presence of a live foetus. The TA convex probe was used from days 40-89 to measure CRL and from days 40-109 to measure BPD. The relation between gestational age and CRL or BPD were highly significant ($p < 0.0001$). The accuracy of sex identification among the three groups was not significantly ($p > 0.05$) higher in single, compared to multiple pregnancies. In total, 83.3% and 70.2% of single and twins and triplets were sexed. After birth, one case was misdiagnosed by ultrasound, i.e. 83.3% (single) and 68.4% (twins and triplets) were sexed. However, identification of GT in male foetuses was possible from day 40 onwards. From a

total 105 scanned does, 80 (76.2%) were sexed and 75.2% of cases were sexed after birth. B-mode real-time ultrasonography is recommended as a reliable means that can be used in field conditions to provide early detection of gestation as early as 19-27 days after mating, for CRL or BPD measuring and foetal sexing from day 40 of gestation onwards.

Keywords

Baladi, Birth, Egypt, Genital tubercle, Goat, Pregnancy, Sexing, Ultrasonography.

Diagnosi precoce di gravidanza e misurazione dei parametri fetali nelle capre egiziane Baladi (*Capra hircus*)

Riassunto

Il presente lavoro mostra l'utilizzo dell'ecografia B-mode transrettale (TR) e transaddominale (TA) nella diagnosi precoce e nella misurazione fetale. Sono state utilizzate 110 capre di età compresa tra 8-36 mesi; è stata quindi eseguita una diagnosi precoce di gravidanza e quindi il numero di feti. È stata determinata la correlazione tra il periodo di gestazione, la lunghezza fetale vertice-sacro (crown-rump length: CRL) e il diametro biparietale (DBP) a 40-109 giorni dalla gestazione. L'accuratezza nella determinazione del sesso del feto è stata determinata attraverso la differenziazione del tubercolo genitale (TG) a 40-109 giorni dalla gestione e successivamente verificata alla nascita. L'esame ha evidenziato il 95,5% di capre gravide con il 100% di accuratezza nella diagnosi di gravidanza dei casi positivi. Nel 45,7% dei casi è

Department of Theriogenology, Faculty of Veterinary Medicine, Zagazig University, El-Zeraa street 34, 1134 Zagazig, Egypt
amer_vet@hotmail.com

stato rilevato un singolo feto, nel 54,3% gemellare o trigemino. La sonda TR ha consentito un riconoscimento affidabile e precoce del fluido fetale (a 5 giorni) e dei battiti cardiaci (a 4 giorni) rispetto alla sonda TA. L'osservazione TR dei battiti cardiaci è raccomandata come prova conclusiva della presenza di feto vitale. La sonda convessa TA è stata utilizzata a 40-89 giorni per misurare il CRL e a 40-109 giorni per il DBP. La correlazione tra l'età gestazionale e il CRL o il DBP è risultata altamente significativa ($p < 0.001$). L'accuratezza nell'identificazione del sesso nei tre gruppi non è stata significativamente superiore ($p > 0.05$) nei casi di feto singolo rispetto alle gravidanze multiple. In totale è stato determinato il sesso nell'83,3% di gravidanze con un solo feto e nel 76,2% in quelle gemellari o trigemine. Alla nascita in un solo caso si è verificato un errore diagnostico, quindi è stato determinato il sesso nell'83,3% (singolo feto) e nel 68,4% (gravidanze gemellari o trigemine). E' stato possibile identificare il tubercolo genitale nei feti di sesso maschile da 40 giorni in poi. Su un totale di 105 capre esaminate, di 80 (76,2%) è stato determinato il sesso e nel 75,2% dei casi si è avuta conferma alla nascita. L'ecografia B-mode real time viene raccomandata come strumento affidabile utilizzato sul campo per la diagnosi precoce di gestazione sin da 19-27 giorni dall'accoppiamento; il CRL o la misurazione del DBP e la determinazione del sesso a partire da 40 giorni dalla gestazione.

Parole chiave

Baladi, Capra, Determinazione del sesso, Ecografia, Egitto, Gravidanza, Nascita, Tubercolo genitale.

Introduction

A reliable means of distinguishing pregnant from non-pregnant goats would enable herdsmen to remove non-pregnant animals from flocks and thereby save on expenses for feed, labour, vaccination, etc. Moreover, special attention and supplementary feed would then be available for pregnant animals. Until recently, no practical means of early pregnancy detection was available for goats. The real time (B-mode) ultrasonography has been available since the early 1980s; however it is considered too time consuming and

expensive for use in farm animals (35). This technique has proved to be a reliable mean for pregnancy detection in a number of domestic species (17). Although there are many reports on the use of transcutaneous and transrectal ultrasonography (8, 19, 34), there is a paucity of information on the accuracy of this technique in goats. The existing literature is limited to the use of transabdominal transducers (15, 22). A single paper by Martinez *et al.* (25) presents data on pregnancy detection using transrectal ultrasonography on 11 pregnant and 5 non-pregnant Nubian does and another study is available on pregnancy diagnosis in Saanen goats (1). The ultrasonic measurement of bi-parietal diameter BPD is routinely performed during human prenatal examination and estimation of gestation age. However, ultrasound-derived BPD and crown-rump length (CRL) data have been reported for various breeds of goats, sheep and red deer (23). Foetal sexing in goats is more appropriate because it will lead to better planning during the marketing of fetuses while still *in utero* (6). Foetal sexing in small ruminants is still not widely applied in Egypt, especially in field conditions, because multiple gestations can lead to false diagnoses and reduce the accuracy of the method. The objective of this study is to compare the transrectal and transabdominal ultrasonography approaches for early detection of pregnancy, to determine the relationship of gestational age with the measurements of CRL and BPD and to determine the accuracy of early foetal sex determination in goats.

Materials and methods

Animals

A total of 110 dairy Baladi goats (*Capra hircus*) aged between 10 and 60 months were used in the study. They were housed and managed on a dairy farm located in the Province of Sharkia. Thirty-five of them were nulliparous, the remainder were multi-parous. They were fed green fodder twice a day and concentrates (16%); they had free access to water and mineral supplements. Oestrus was carefully observed and does were naturally mated twice

on the first and second day of oestrus. Thus, the first day of oestrus was designated to be day 0 of gestation. The study extended from March to December 2007.

Ultrasound equipment

Measurements were conducted using a B-mode, real-time scanner (Pie-medical, model Genus-240 Parus) equipped with a 6-8 MHz linear-array transducer for transrectal ultrasonography and a 3.5-5 MHz sector-array transducer for transabdominal ultrasonography.

Ultrasound scanning and early pregnancy detection

Using the transrectal approach, faeces were cleared from the rectum (does usually defecate as soon as a finger or transducer enters the rectum) and a well lubricated 6 MHz transducer with carboxymethyl-cellulose conducted gel was introduced. The transducer was advanced gently until the urinary bladder became visible on the monitor, where the uterine horns are located in a cranial position. The entire reproductive tract was inspected by moving the probe gently backwards and forwards and rotating it 90° clockwise and counter-clockwise. It was sometimes helpful to manually push the abdomen upwards just in front of the hind legs to get the uterus within the range of the transducer as reported by Haibel (13) and Kaehn (16). To conduct transabdominal ultrasonography, an area of 100-200 cm² of the coat on the right side, just above the udder, had to be clipped. The 3.5 MHz-transducer, covered with conducted gel, was applied as described in detail by both Haibel (13) and Hesselink and Taverne (15). The goats were inspected with both the rectal and abdominal probes at three-day intervals from day 15 onwards after mating until being conclusively diagnosed as pregnant (positive diagnosis was confirmed on two successive days).

Measuring of foetal crown-rump-length and bi-parietal diameter

To measure the CRL, scanning was performed at weekly intervals at days 40 to 89 of gestation. The criteria for measuring the CRL in human beings were used. The

measurements were taken from the crown (most upper part of the skull) to the buttocks (end of the sacrum) when the foetus was fully extended. To measure the BPD, scanning was performed at weekly intervals at days 40 to 109 of gestation. Scanning of the head was conducted on the transverse axial plane. The criteria for measuring the BPD were as follows: as oval a shape as possible, closed contour of the skull table, flax cerebri mid-line dividing the hemispheres into two equidistant parts and measurements were taken from the outer surface of the proximal calvarium to the inner surface of the distal calvarium.

Foetal sex determination

The sex of the foetus was determined by visualising the external genitalia (penis, prepuce, scrotal bag, nipples and genital swelling) and/or localising the GT described by Reichenbach *et al.* (31). The does were classified into three groups according to the gestation age, from days 40 to 60 (examined TR), from days 61 to 70 (examined TR) and from days 71 to 109 (examined TA). The foetus was recorded as a male when the GT was located immediately caudal to the umbilical cord and as a female when it was located near the tail. After birth, the sex of foetuses was confirmed by recording the number and sex of lambs born.

Statistical analysis

The early pregnancy data and ultrasonic parameters (CRL, BPD) were subjected to analysis by SPSS version 11.5 (11). The accuracy of diagnosis between single and multiple pregnancies was analysed using the Fisher exact test, while the Chi-square test was used to examine positive or negative results, as well as foetal sexing among the experimental groups.

Results

The percentage and accuracy of ultrasound in pregnancy diagnosis were 95.5% and 100% for positive cases, respectively (Table I). This was confirmed at delivery. An animal was considered pregnant when the fluid filled the gestational sac in the uterus, and the

cotyledons and/or foetal parts were recognised. In regard to foetal number, the single and multiple pregnancies detected were 45.7 and 54.3%, respectively. The animal was designed as bearing twins when two heads and/or two beating hearts and/or two bodies were recognised. All foetuses were viable according to their movement or heart beats.

The first thing that could be visualised by the TR probe was a small non-echogenic vesicle, about 1 cm in diameter, situated in the uterine lumen. This could be reliably detected from day 19.5±0.3 onwards. Three and half days later, on day 22.9±0.7, the foetal heartbeat was recognisable. With the TA probe, fluid-filled vesicles were reliably located from day 24.7±0.4 onwards, whereas the foetal heartbeat was first seen as late as day 27.0±0.6 (Table I; Fig. 1). The difference between TR and TA recognition of pregnancy was significant for both foetal fluid and heartbeat ($p<0.01$).

The measurements for CRL from day 40 to day 89 and for BPD from day 40 to day 109 of gestation were taken as shown in Table II and Figure 1. Gestational equations were established for the CRL and BPD as follows: $CRL=0.464x-17.767$ and $BPD=0.055x-1.431$, where x is the gestational age in days. The correlation between the gestational age and CRL and between the gestational age and BPD was found to be highly significant ($p<0.0001$).

The sex of the foetus was determined during three stages of pregnancy (Table III; Fig. 1). During the first stage, sex determination was performed 40 to 60 days after mating. Out of 30 pregnant goats, there were 100% (16/16) single and 85.7% (12/14) multiple pregnancies

that could be sexed. During the second stage, (61 to 70 days after mating), out of 38 pregnant goats, there were 83.3% (15/18) single and 80% (16/20) multiple pregnancies that could be sexed. At 90 to 109 days after mating, out of 37 pregnant goats, there were 64.3% (9/14) single and 52.3% (12/23) multiple pregnancies that could be sexed. The accuracy of sex diagnosis did not differ ($p>0.05$) between single and multiple pregnancies during each of three stages of pregnancy. Single and multiple goats were sexed in 83.3% and 70.2% of cases, respectively. After birth, one case was misdiagnosed by ultrasound i.e. 83.3% and 68.4% for single and multiple pregnancies were sexed.

Discussion

In this study, the accuracy of ultrasound was 100% when detecting pregnant and non-pregnant cases, this is in agreement with Medan *et al.* (26) and Gonzalez *et al.* (12) who found accuracy levels of 100% and 98.7%, respectively. Concerning the number of foetuses, the accuracy for detecting singles and multiples were 45.7% and 54.3%, respectively. Goel and Agrawal (10) reported that it is difficult to differentiate between twins and triplets or quadruplets at any stage of gestation while Karen *et al.* (20) reported that the accuracy of ultrasound in detecting ewes carrying two foetuses or more was disappointing. McGahan and Coats (24) reported that multiple pregnancies should be reported in instances where multiple embryos are detected, due to variability in fusion performed in Egypt, high accuracy levels were

Table I

The accuracy of transrectal and transabdominal ultrasound in pregnancy diagnosis based on the visibility of foetal fluids or foetal heart beats in goats
Values of early detection of pregnancy were significantly different ($p<0.01$) using the Chi-square test

Transrectal and transabdominal ultrasound	Total number of examined goats (n=110)			
	Number (%)	Accuracy (%)*	Single	Twins and triplets
Positive cases	105/110 (95.5)	105/105 (100)	48/105 (45.7)	57/105 (54.3)
Negative cases	5/110 (4.5)	5/5 (100)	-	-
Early detection of pregnancy (days)	Foetal fluid		Heart beats	
	Transrectal	Transabdominal	Transrectal	Transabdominal
	19.5±0.3	24.7±0.4	22.9±0.7	27.0±0.6

* determined after successive examinations of positive and negative cases

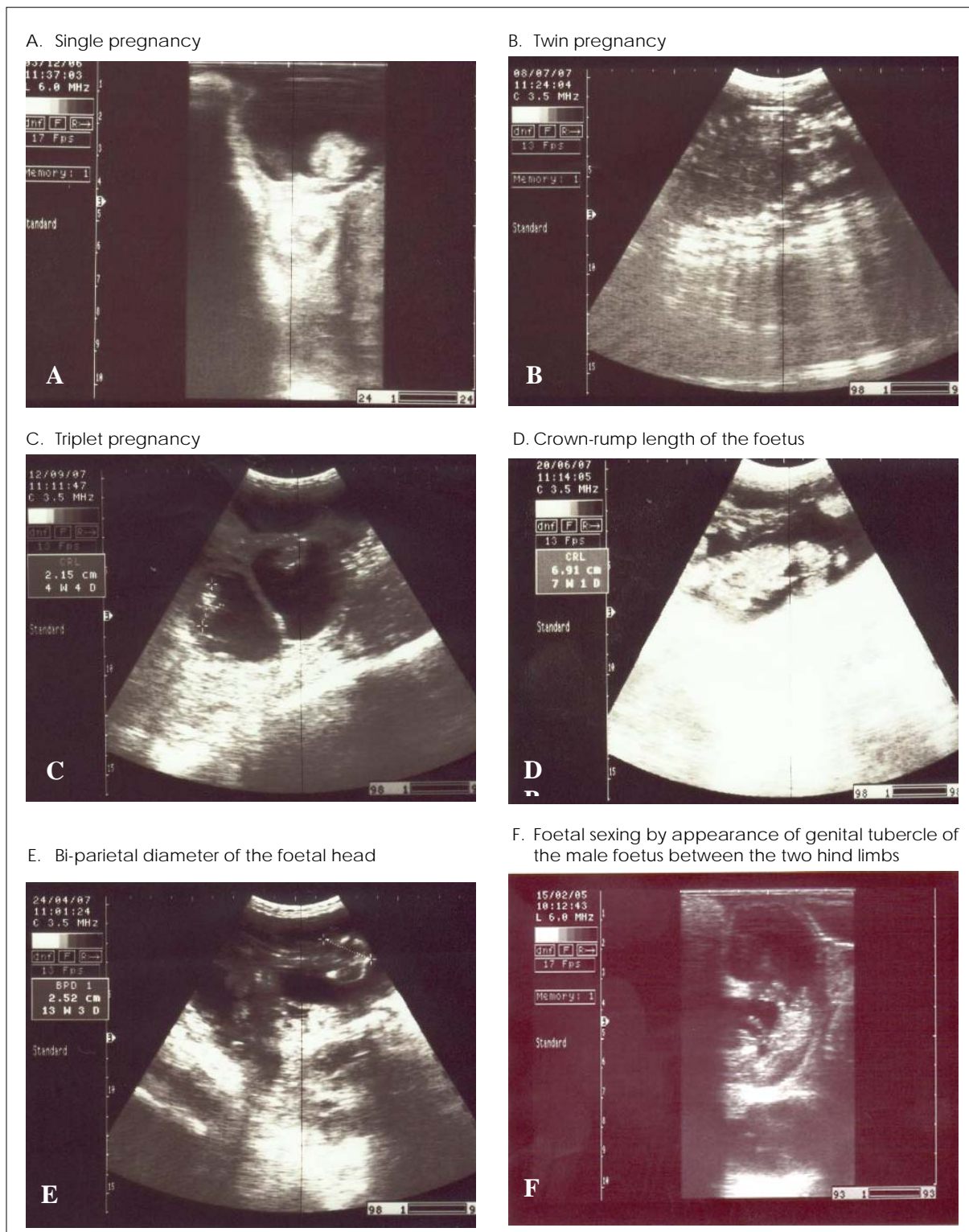


Figure 1 Ultrasonographic images showing early pregnancy detection and fetometry in goats

obtained due to the appropriate technique adopted for this study. Adequate fasting of the animals helps to evacuate the gastrointestinal tract from gasses which facilitates the transmission of sound waves. Careful shaving

and clipping provided suitable contact between the probe and the animal. Karen *et al.* (21) found that sensitivity of ultrasound scanning for early pregnancy in ewes by using 5 MHz transrectal probe was lower in the

Table II
 Ultrasonic measurement of foetal crown-rump length and bi-parietal diameter from day 40 to day 109 of gestation using transrectal probes
 Correlations between the gestation age and either crown-rump length or bi-parietal diameter was found to be highly significant ($p < 0.0001$)

Gestation age (days)	Foetal measurements (cm) using transrectal ultrasound (n=16)	
	Crown-rump length	Bi-parietal diameter
40-49	3.59±0.16	1.19±0.03
50-59	7.16±0.20	1.51±0.04
60-69	9.47±0.23	1.85±0.03
70-79	11.21±0.25	2.24±0.04
80-89	13.65±0.20	2.70±0.06
90-99	-	3.03±0.12
100-109	-	3.62±0.07

absence of fasting and without lifting of the abdominal wall in comparison to scanning-diagnosis after fasting for 12 h.

Almost all previous investigations that examined pregnancy detection in goats with the aid of real-time ultrasonography, except that conducted by Martinez *et al.* (25), used abdominal transducers. It was reported that pregnancy could be diagnosed between four and five weeks after mating (13, 15, 18). In our investigation, reliable results were achieved slightly earlier, which may be explained by the use of a 3.5 MHz transducer; this wavelength enabled a greater distance than the 5 MHz transducers used in most of the other studies (3). The present study constitutes one of the few recent known direct comparisons of transabdominal and transrectal measurements

in goats. It shows that a rectal probe enables the detection of pregnancy 4-5 days earlier than when a transabdominal probe is used. The 6-8 MHz rectal probe, designed to view close objects, delivered a high resolution and a clear image at close range. In spite of using a 5 MHz rectal probe of lower resolution, Martinez *et al.* (25) were able to detect pregnancies two days earlier than the cut-off time obtained in this study.

The use of a transabdominal transducer may be more convenient and time-saving. However, rectal probes are preferred since pregnancy can be detected 4-5 days earlier and a clearer, more easily interpretable image is usually obtained. The foetal heartbeat can only be recognised at three or more days later than the fluid accumulation in the uterus. It is worth noting that the heart beat indicator provides conclusive evidence of the presence of a live foetus.

In spite of repeated exposure of the foetuses to ultrasonic waves of two different wavelengths (3.5 and 6 MHz), no foetal deaths or abortions occurred in this study and all the kids born were morphologically normal and viable. Similar observations have been observed in sheep by various investigators (13, 29).

Although ultrasound is commonly used for the measurements of CRL and BPD in pregnant sheep and goats (2, 23), in the present study, CRL and BPD could be measured with ease from days 40 to 89 and from days 40 to 109 of gestation, respectively, and the techniques correlated perfectly with gestational age.

Table III
 Accuracy transrectal and transabdominal ultrasound in foetal sex identification between days 40 to 109 of gestation in goats
 Values did not differ significantly ($p > 0.05$)

Gestation age (days)	Sex determination ^(a) : number (%)		
	In single births	In births of twins and triplets	Total
40-60 (transrectal)	16/16 (100)	12/14 (85.7)	28/30 (93.3)
61-70 (transrectal)	15/18 (83.3)	16/20 (80)	31/38 (81.6)
90-109 (transabdominal)	9/14 (64.3)	12/23 (52.3)	21/37 (56.8)
Total	40/48 (83.3)	40/57 (70.2)	80/105 (76.2)
After birth ^(b)	40/48 (83.3)	39/57 (68.4)	79/105 (75.2)

a) determination and/or localisation of genital tubercle indicating male foetuses
 b) results obtained by detection of sex after birth

Santiago-Moreno *et al.* (32) measured the CRL and BPD from day 25 onwards in a mouflon (*Ovis gmelini musimon*) and found a strong correlation between the gestational age and each of the two parameters. Similarly, a high correlation between the gestational age and the BPD has been observed in ewes (2) between days 36-102 after mating (23). After day 89 of gestation, it was not possible to measure the CRL because the foetus was beyond the limits the screen. The BPD was also difficult to measure after day 109 of gestation due to the increase in foetal size and compression of the head by other foetal parts. Similar difficulties in measuring the BPD during the late stage were found in llama (14) and during the later stages of pregnancy in ungulate species (30). Gestational equations derived could be used with confidence to estimate the gestational period in goats of known date of natural mating. In our present study, parturition of all animals occurred within the normal range of gestation i.e. 146 ± 0.6 days.

The accuracy of diagnosis in single pregnancies performed at days 40-60 of gestation (100%) was higher than that obtained by Coubrough and Castell (7) and Buerstel *et al.* (4). Coubrough and Castell (7) reported that it was not possible to identify the foetal sex in 7% of the animals between days 60-69 post-mating by transrectal ultrasonography. In the present study, the ultrasonographic presentation of the foetus at the time of examination and the number of examinations performed on the same animal improved diagnosis. To obtain a high accuracy of foetal sexing, it is essential to perform a sequence of examinations at intervals of 24, 48 or 72 h or even at longer intervals as suggested by Buerstel *et al.* (5) and Reichenbach *et al.* (31). In the present study, daily examinations did not improve diagnosis. The incorrect position of the foetus, obstructing the visualisation of anatomic structures used for sex determination, is a characteristic that impairs ultrasound scanning especially in multiple pregnancies. Incorrect quantification and foetal sex diagnosis associated with foetus interposition (5) has also been reported previously by other investigators (9, 13).

Accuracy in foetal sexing in small ruminants depends more on the time of GT migration, particularly in goats. According to Olivera *et al.* (28), in foetuses of American Alpine goat, the migration of the GT occurs around day 46.4 ± 2.1 of pregnancy and in Saanen goats on day 48.9 ± 1.8 . In the present study, the migration of the GT also occurred around day 50 of pregnancy. Although the beginning of GT migration occurs after day 46, it is suggested that examinations be performed between days 55 and 70 of pregnancy to avoid mistakes resulting from individual and breed specific variations.

During days 61-70 of pregnancy, satisfactory results were obtained (83.3% and 80% for single and multiple cases sexed) with single examinations. In field conditions, Reichenbach *et al.* (31) recommended repeating the examination at least once to optimise results. The GT position for sexing is better defined from day 55 of pregnancy onwards. The determination of foetal sex by abdominal ultrasonography in small ruminants can be performed between days 50-70 of pregnancy (4) or between days 65 to 100 (27). In multiple pregnancies, two successive examinations have been recommended. The first examination should be between days 50-56 and the second examination between days 66-70 of pregnancy (4). During days 90-109, unsatisfactory results (64.3 and 52.3% for single and multiple pregnancies) were sexed in single examinations performed in the last third of pregnancy. Higher rates could be obtained by rectal examinations (31). The false diagnosis during this stage probably occurred due to the age and size of the conceptuses, which reduces the space in the uterus and, consequently, the placenta and other foetal annexes, as well as the foetus itself, may be incorrectly interpreted as hyperechoic organs related to sexual differentiation. In a previous study using goats of Anglo-Nubian breed, Santos *et al.* (33) concluded that foetal sex determination by ultrasonography in goats should not be performed after day 100 of pregnancy, especially in multiple pregnancies. However, after birth, one case was misdiagnosed by ultrasound i.e. 83.3 and 68.4% for single and

multiple births were compared to the total sexing by ultrasound (83%.3 and 70.2% of single and multiple births).

Conclusion

Real-time ultrasonography is a convenient, safe and reliable means of early pregnancy detection in goats from day 19.5±0.3 onwards. It is the accurate method for the determination of foetal numbers, as well as for the identification of sex and prediction of gestational age and calving date in field conditions.

References

1. Abdelghafar R.M. 2006. B-mode real time ultrasonography for pregnancy diagnosis and fetometry in Saanen goats. MSc thesis, Sudan University of Science and Technology, Khartoum, 71 pp.
2. Aiumlamai S., Fredriksson G. & Nilsfors L.L. 1992. Real-time ultrasonography for determining the gestational age of ewes. *Vet Rec*, **131**, 560-562.
3. Buckrell B.C. 1988. Application of ultrasonography in reproduction in sheep and goats. *Theriogenol*, **29**, 71-84.
4. Buerstel D., Meinecke-Tillmann S. & Meinecke B. 2001. Ultrasonographic determination of sex in small ruminants. In Fifth annual conference of the European Society for domestic animal reproduction, 13-16 September, Vienna. *Dom Anim Reprod*, **6**, 53-54.
5. Buerstel D., Meinecke-Tillmann S. & Meinecke B. 2002. Ultrasonographic diagnosis of foetal sex in small ruminants bearing multiple foetuses. *Vet Rec*, **151**, 635-636.
6. Chalhoub M. & Ribeiro Filho A.L. 2002. Diagnóstico de gestação em pequenos ruminantes por ultrasonografia de tempo real. *Rev Brasil Reprod Anim*, **26**, 27-30.
7. Coubrough C.A. & Castell M.C. 1998. Fetal sex determination by ultrasonically locating the genital tubercle in ewes. *Theriogenol*, **50**, 263-267.
8. Garcia A., Neary M.K., Kelly G.R. & Pierson R.A. 1993. Accuracy of ultrasonography in early pregnancy diagnosis in the ewe. *Theriogenol*, **39**, 847-861.
9. Gearhart M.A., Wingfield W.E., Knight J.A., Smith J.A., Dargatz D.A., Boon J.A. & Stokes C.A. 1988. Real-time ultrasonography for determining pregnancy status and viable foetal numbers in ewes. *Theriogenol*, **30**, 323-337.
10. Goel A.K. & Agrawal K.P. 1992. A review of pregnancy diagnosis techniques in sheep and goats. *Small Rumin Res*, **9**, 255-264.
11. Gomez K.A. & Gomez A.A. 1984. Statistical procedure for agricultural research, 2nd Ed. John Wiley and Sons Inc., New York, 680 pp.
12. Gonzalez F., Cabrera F., Batista M., Rodriguez N., Alamo D., Sulon J., Beckers J. & Anselmo G. 2004. A comparison of diagnosis of pregnancy in the goat via trans-rectal ultrasound scanning, progesterone and pregnancy-associated glycoprotein assays. *Theriogenol*, **62**, 1108-1115.
13. Haibel G.K. 1990. Use of ultrasonography in reproductive management of sheep and goat herds. *Vet Clin North Am Pract*, **6**, 597-613.
14. Haibel G.K. & Fung E.D. 1991. Real time ultrasonic biparietal diameter measurement for the prediction of gestational age in llamas. *Theriogenol*, **35**, 683-587.
15. Hesselink J.W. & Taverne M.A. 1994. Ultrasonography of the uterus of the goat. *Vet Q*, **16**, 41-45.
16. Kaehn W. 1991. Atlas and textbook of ultrasound diagnostic: gynaecologic examination and reproduction: mare, cow, ewe, goat, sow, bitch, cat. Schluetersche, Hannover, 15-22.
17. Kaehn W. 1992. Ultrasonography as a diagnostic tool in female animal reproduction. *Anim Reprod Sci*, **28**, 1-10.

Acknowledgements

The author wishes to extend his gratitude to the owner of the farm at Abu-Kabeer, Sharkia-Province, for their help and advice. In addition, sincere thanks are extended to all the staff members of the Department of Theriogenology at the Faculty of Veterinary Medicine of Zagazig University, for their assistance and advice.

18. Kaehn W., Fraunholz J., Kaspar B. & Pyczak T. 1990. Die sonographische Fruehtraechyigkeitsdiagnose bei Pferd, Rind, Schaf, Ziege, Schwein, Hund und Katze – Richtwerte und Grenzen. (Sonography for early pregnancy diagnosis in horses, cattle, sheep, goats, swine, dogs and cats: capabilities and limits.) *Berl Munch Tierarztl Wschr*, **103**, 206-211.
19. Kaehn W., Achtzehn J., Kaehn B., Richter A., Schulz J. & Wolf M. 1993. Sonography of pregnancy in sheep. II: Accuracy of transrectal and transcutaneous pregnancy diagnosis. *Dtsch Tierarztl Wochenschr*, **100**, 29-31.
20. Karen A., Kovaccs P., Beckers J.F. & Szenic O. 2001. Pregnancy diagnosis in sheep: review of the most practical methods. *Acta Vet Brno*, **70**, 115-126.
21. Karen A., Szabados K.K., Reicziegel J., Beckers J.F. & Szenic O. 2004. Accuracy of trans-rectal ultrasonography for determination of pregnancy in sheep: effect of fasting and handling of the animals. *Theriogenol*, **61**, 1291-1298.
22. Kaulfuss K.H., Zipper N., May J. & Suess R. 1996. Pregnancy diagnosis by B-mode ultrasonography in sheep. Part 2: Comparison of transcutaneous and transrectal diagnosis. *Tieraerztl Praxis*, **24**, 559-566.
23. Lee Y., Lee O., Cho J., Shin H., Choi Y., Shim W., Choi W., Shin H., Lee D. & Shin S. 2005. Ultrasonic measurements of fetal parameters for estimation of gestational age in Korean black goats. *J Vet Med Sci*, **67**, 497-502.
24. McGahan J.P. & Coats T.L. 1996. Obstetrical ultrasound: normal anatomy and measurements. In *The Nicer Year Book: Ultrasonography* (B.B. Goldberg & H. Pettersson, eds). Elanders Norge AS, Oslo, 307-340.
25. Martinez M.F., Bosch P. & Bosch R.A. 1998. Determination of early pregnancy and embryonic growth in goats by trans-rectal ultrasound scanning. *Theriogenol*, **49**, 1555-1565.
26. Medan M., Watnabe G., Absy G., Sasaki K., Sharawi S. & Taya K. 2004. Early pregnancy diagnosis by means of ultrasonography as a method of improving reproductive efficiency in goats. *J Reprod Dev*, **50**, 4.
27. Nan D., Van Oord H.A. & Taverne M.A. 2001. Determination of fetal gender in sheep by transabdominal ultrasonographic scanning. In *Fifth annual conference of the European Society for domestic animal reproduction*, 13-16 September, Vienna. *Dom Anim Reprod*, **6**, 70.
28. Olivera M.A., Santos N.H., Moraes E.P., Moura R.T., Chiamenti A., Bezerra F.Q., Rabelo M.C. & Lima P.F. 2005. Early identification of foetal sex and determination of genital tubercle migration's day in dairy goats using ultrasound. *Acta Sci Vet*, **32**, 353.
29. Padilla-Rivas G.R., Sohnerly B. & Holtz W. 2005. Early pregnancy detection by real-time ultrasonography in Boer goats. *Small Rumin Res*, **58**, 87-92.
30. Place N.J., Weldele M.L. & Wahaj S.A. 2002. Ultrasonic measurements of second and third trimester fetuses to predict gestational age and date of parturition in captive and wild spotted hyenas, *Crocuta crocuta*. *Theriogenol*, **58**, 1047-1055.
31. Reichenbach H.D., Santos M.H., Oliveira M.A., Meinecke-Tillmann S. & Buerstel D.M. 2004. Sexagem fetal na cabra e na ovelha por ultra-sonografia. In *Diagnóstico de gestação na cabra e na ovelha* (M.H.B. Santos, M.A.L. Oliveira & P.F. Lima, eds). Varela, Sao Paulo, 117-136.
32. Santiago-Moreno J., González-Bulnes A., Gómez-Brunet A., Toledano-Díaz A. & López-Sebastián A. 2005. Prediction of gestational age by transrectal ultrasonographic measurements in the mouflon (*Ovis gmelini musimon*). *J. Zoo Wildl Med*, **36**, 457-462.
33. Santos M.H., Moraes E.P., Moura R.T., Chiamenti A., Bezerra F.Q., Aguiar-Filho C.R., Lima P.F. & Oliveira M.A. 2005. Foetal sexing in goats by ultrasonography. *Acta Sci Vet*, **32**, 345.
34. Schrick F.N. & Inskeep E.K. 1993. Determination of early pregnancy in ewes utilizing transrectal ultrasonography. *Theriogenol*, **40**, 295-306.
35. Thwaites C.J. 1981. Development of ultrasonic techniques for pregnancy diagnosis in the ewe. *ABA*, **49**, 427-434.

