

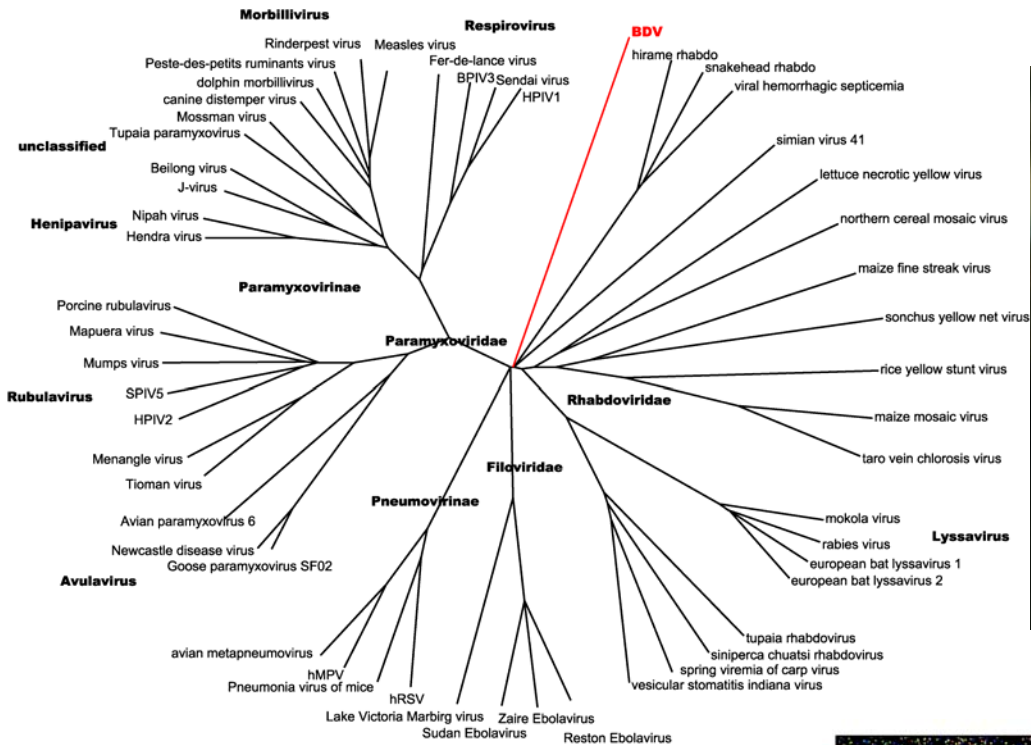


Polly doesn't want a cracker: Identification of a novel avian bornavirus in psittacine proventricular dilation disease



Microarray Workshop, Teramo Italy
15 March 2010
Amy Kistler, Ph.D., M.P.H.
Ganem & DeRisi labs, UCSF

Virochip applications: *Proventricular dilation disease (PDD)*

Identified in 1970s--'Wasting Macaw syndrome'

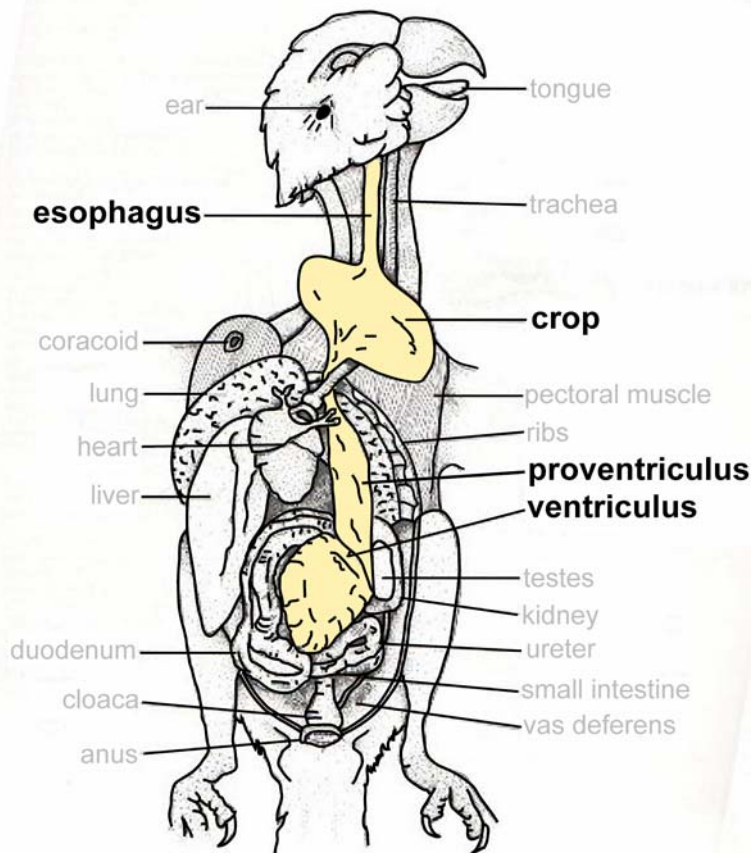
- 100% fatality rate if left untreated
- no preventive or generally accepted therapeutic treatment



But many other *psittacine* species are susceptible

*And...*clinical reports in at least 5 other orders of birds!

PDD: named for clinical hallmark



Disordered peristalsis of upper GI tract
Dilation of proventriculus, abdominal swelling
Regurgitation, poor food absorption
Wasting, bacteria/fungal overgrowth

*CNS lesions--ataxia, encephalitis

Histological hallmarks of PDD: ganglioneuritis

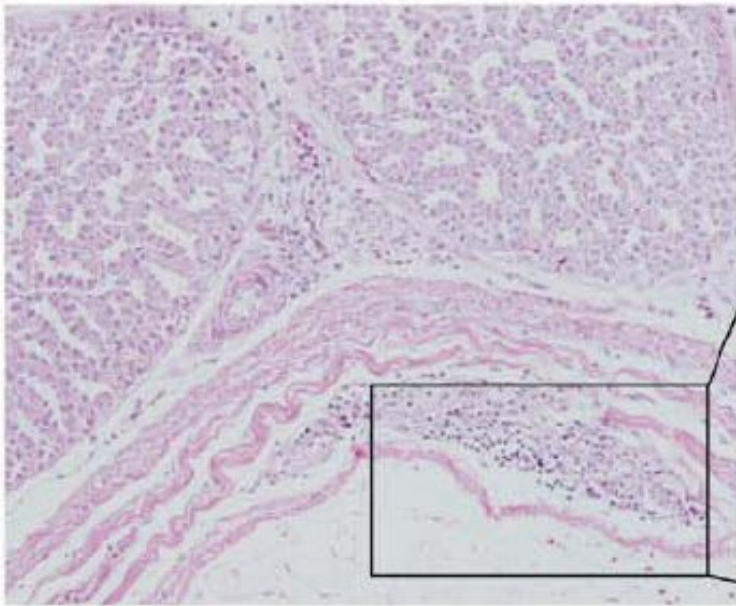


Fig. 2: Mononuclear lymphoplasmacytic infiltrates within a ganglion of proventriculus (X10).

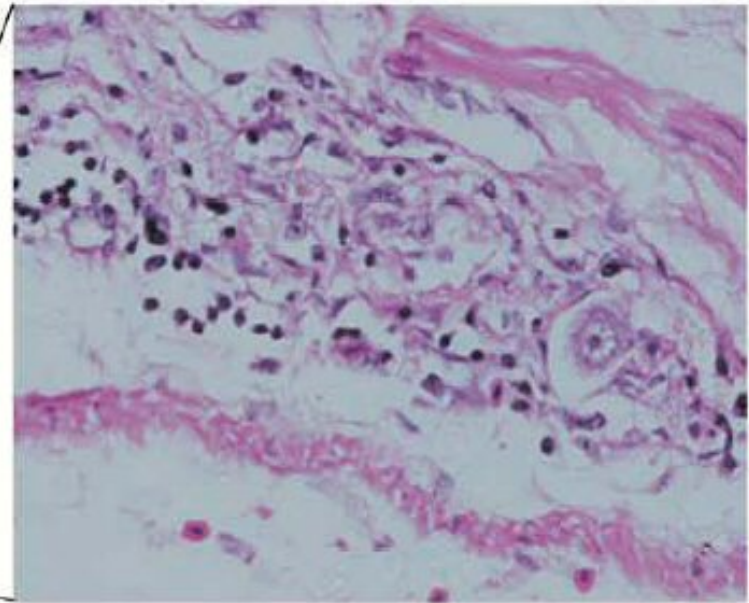
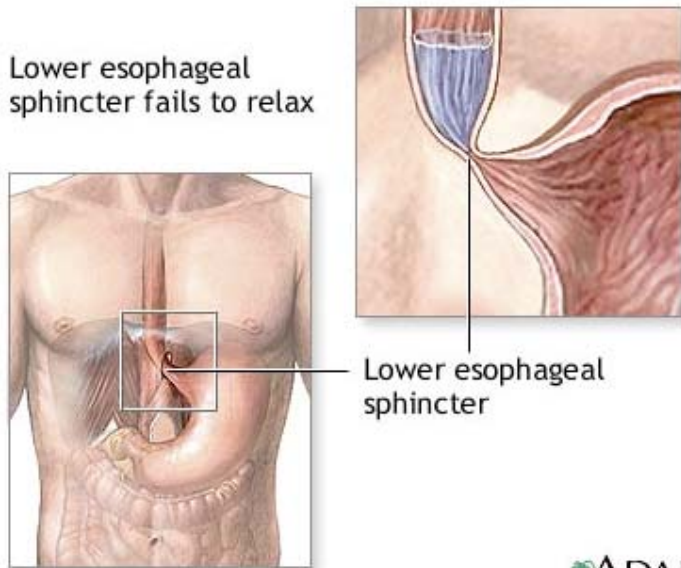


Fig. 3: The ganglion area of Fig. 2, higher power (X40).

Relevance to human disease?

Parallels between PDD and achalasia



Shared clinical hallmarks:

Disordered peristalsis of distal esophagus
Obstruction, esophageal dilatation
Regurgitation, wasting

Similar pathology:

Loss of myenteric ganglia, nerves
Inflammation (CD8+ T cells) precedes neuronal loss.



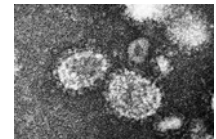
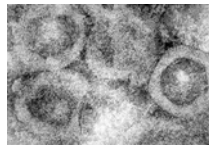

Etiology: unknown

Initial thoughts--degenerative disease
More recently--autoimmune? viral? both??

No known naturally occurring animal model

PDD: evidence for viral etiology

- 1. Observed transmission/outbreaks within aviaries*
- 2. Anecdotal reports of experimental transmission of PDD*

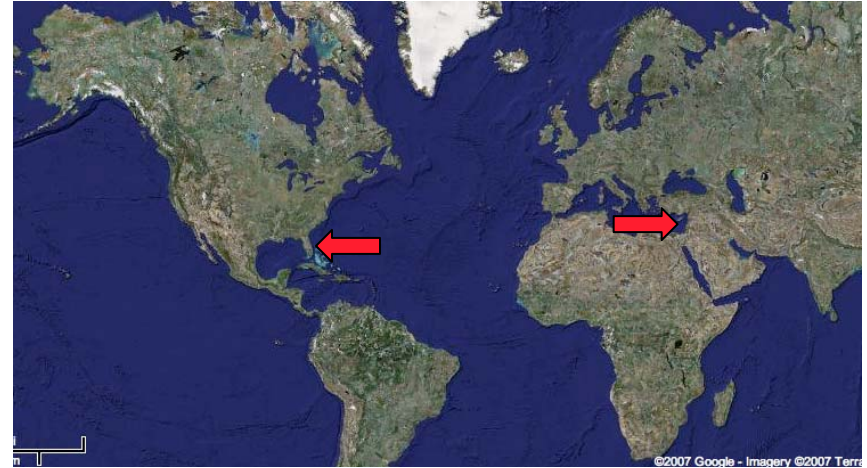


3. Reports of detection of viruses associated with the disorder:

- avian paramyxovirus
- coronavirus


Two sources of PDD specimens

Source 1: Florida
Dr. Susan Clubb, DVM
crop tissue biopsies
5 PDD+, 5 PDD- birds

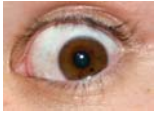


Source 2 = Israel
Dr. Ady Gancz, DVM
RNA + DNA from brain, stomach
6 PDD+, 3 PDD-

Virochip analysis



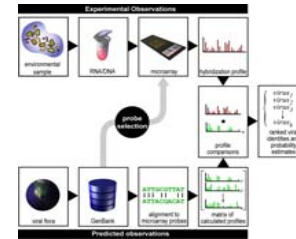
Virochip analysis of PDD case/control series:



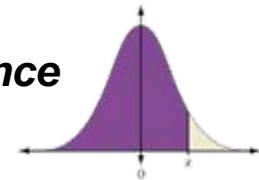
**Visual inspection of each array during scanning
2 oligos with saturating signal never seen before--
present only in cases...**

**Computational analyses
supports visual call....**

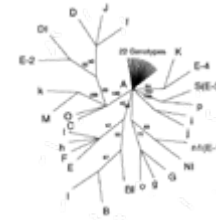
E-predict



***Single oligo performance
(Z-score)***



***Phylogenetic
(vTaxI)***

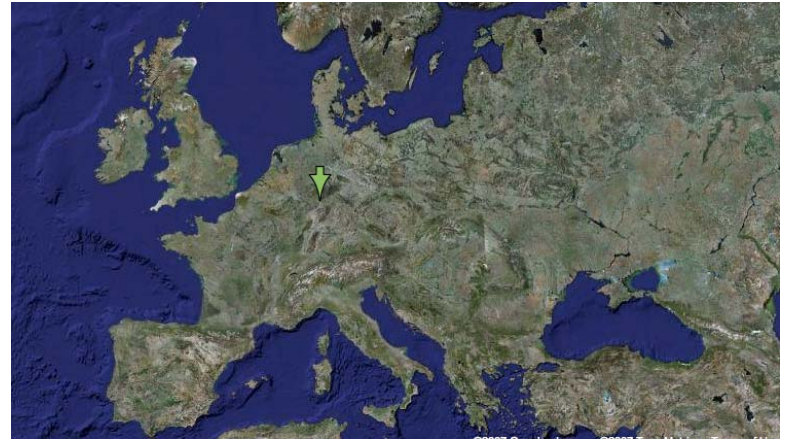

5/8 cases and 0/8 controls contain a bornavirus signature!

Borna disease virus (BDV): history

Named for town of Borna, Germany

1800s (and subsequent years):
Encephalitis outbreaks horses
80-100% fatality rate

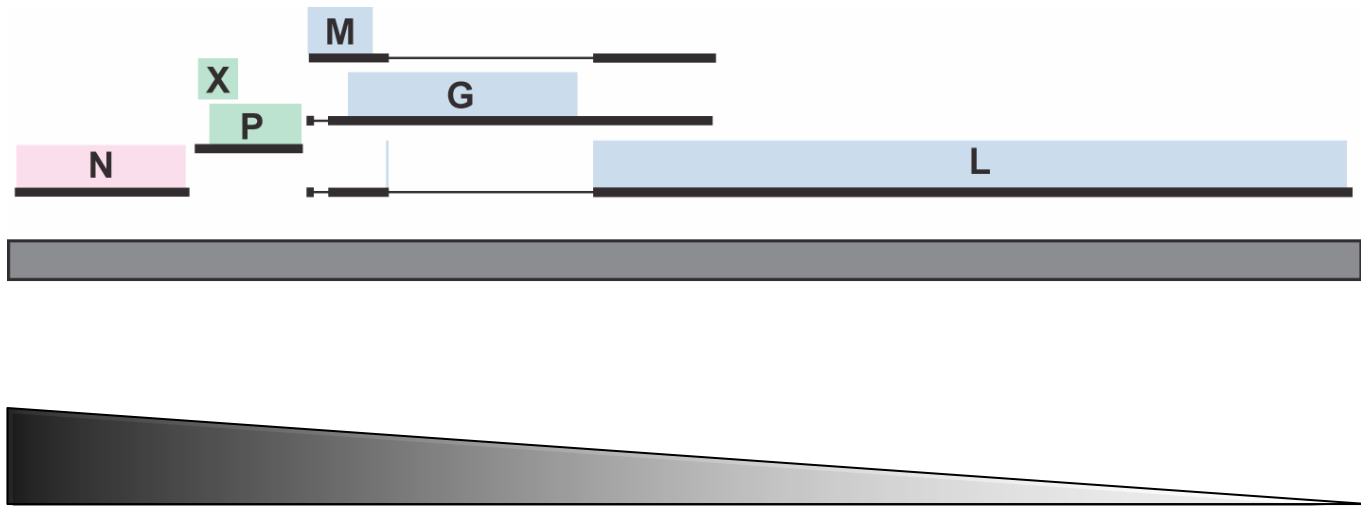


Symptoms:

- ataxia
- 'pipe-smoking': hay in mouth...
but no eating!
- unusual behaviour



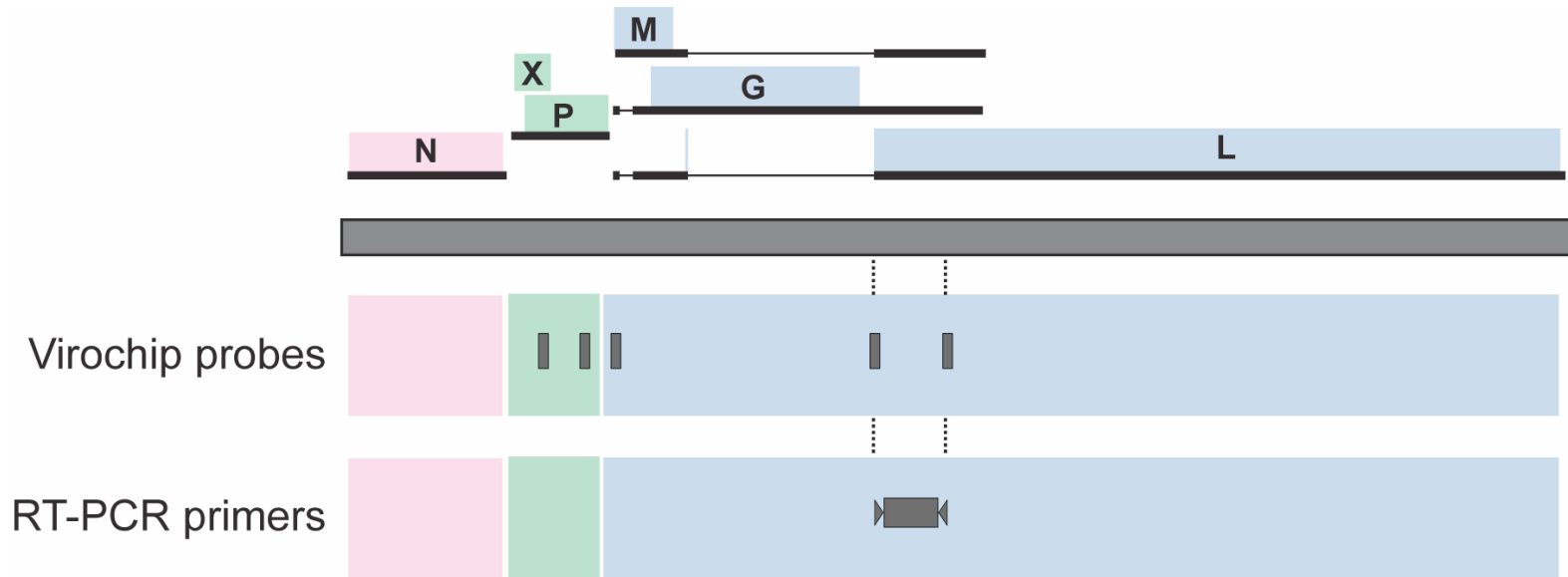
*BDV is a non-segmented
negative stranded RNA virus*



BDV=prototype of Bornaviridae family of viruses

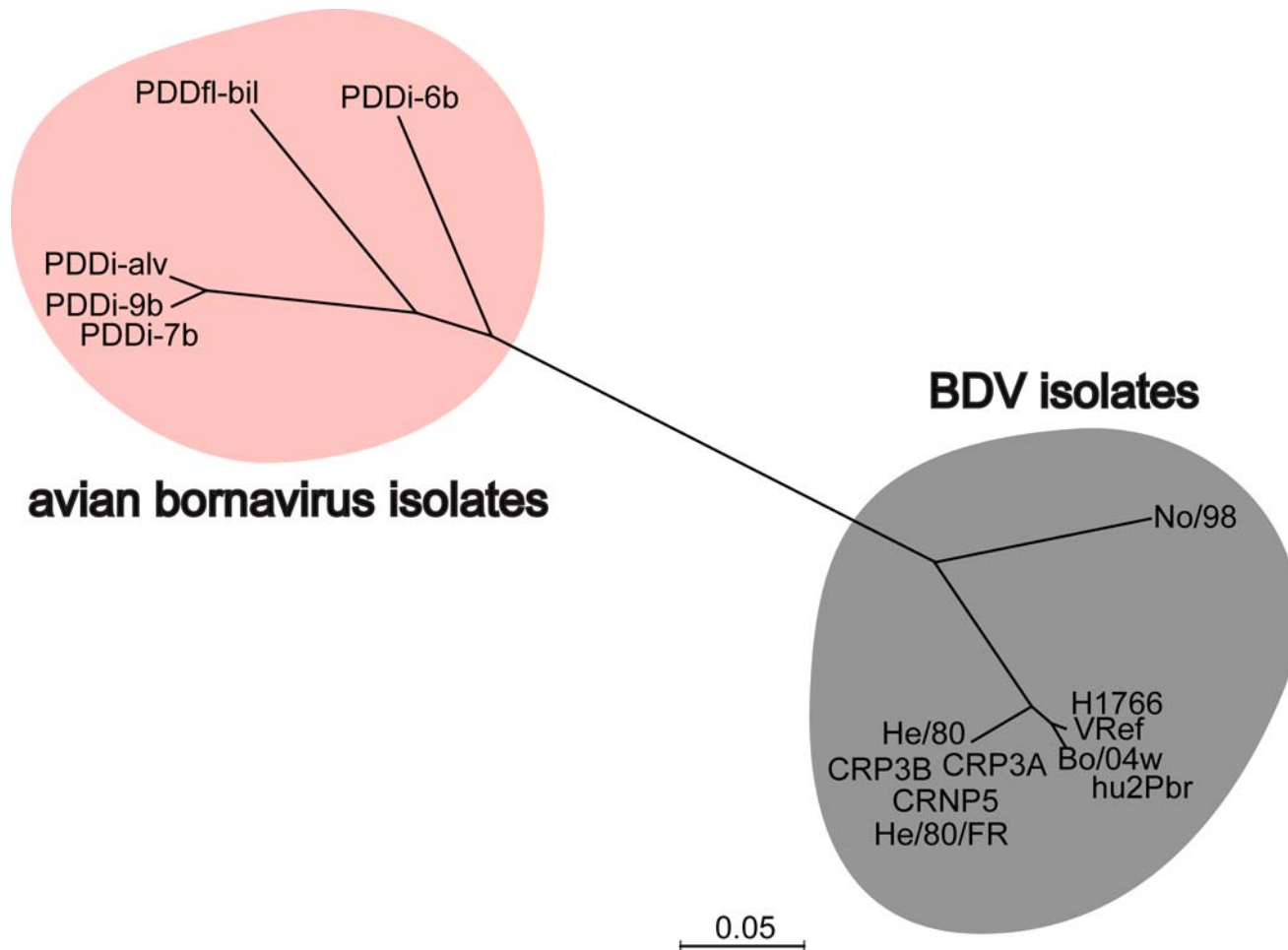
- *Nuclear replication AND pre-mRNA splicing*
- *Little sequence diversity (13/14 genome sequences share >96% identity)*

PCR confirmation & sequence recovery

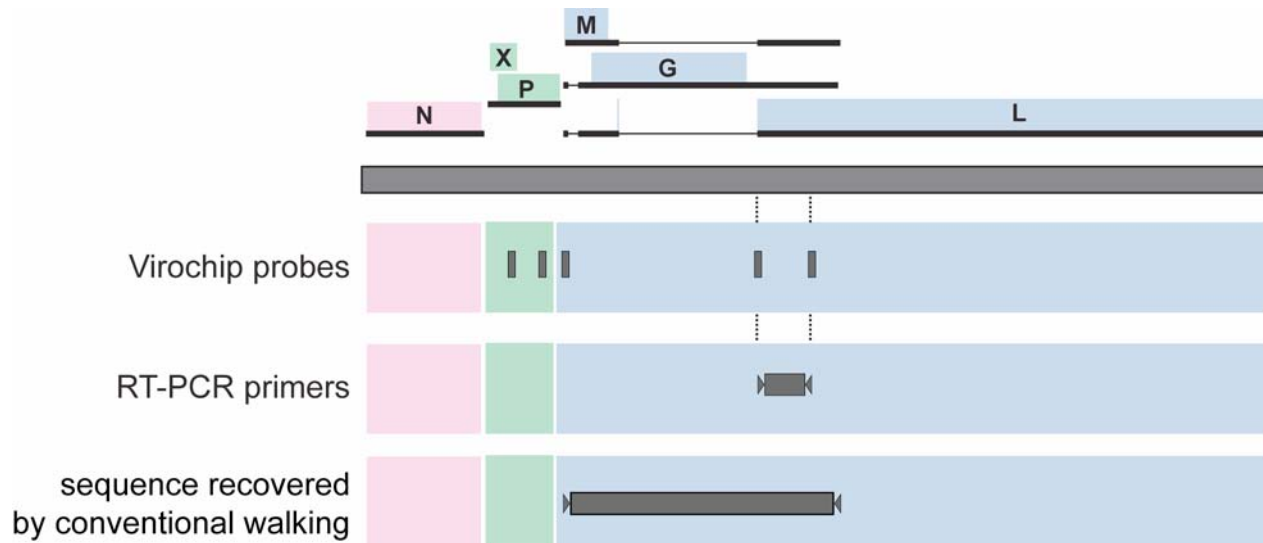


Utilize array probes as a guide for RT-PCR primer design
To directly recover ABV sequence from clinical specimen

Recovered avian bornavirus sequences diverge from known BDVs and each other!




ABV diversity presented a problem for recovery of the entire genome sequence



Multiple efforts to design PCR primers beyond this region based on known BDV sequences failed to yield ABV products from the PDD affected tissues....

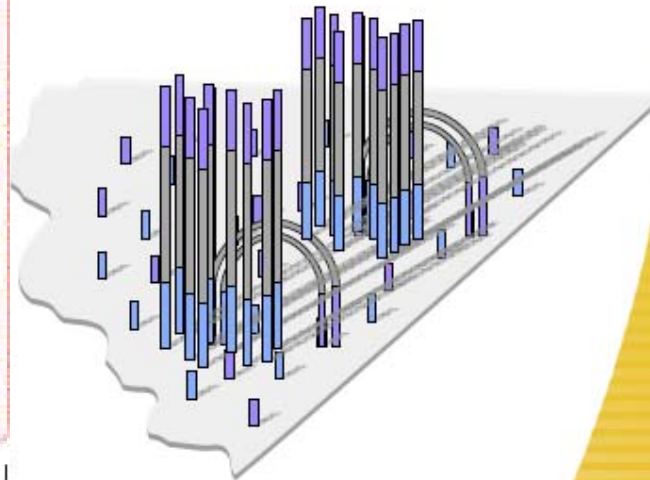
Deep sequencing as a solution?



100um

Random array of clusters

Amplify to form clusters

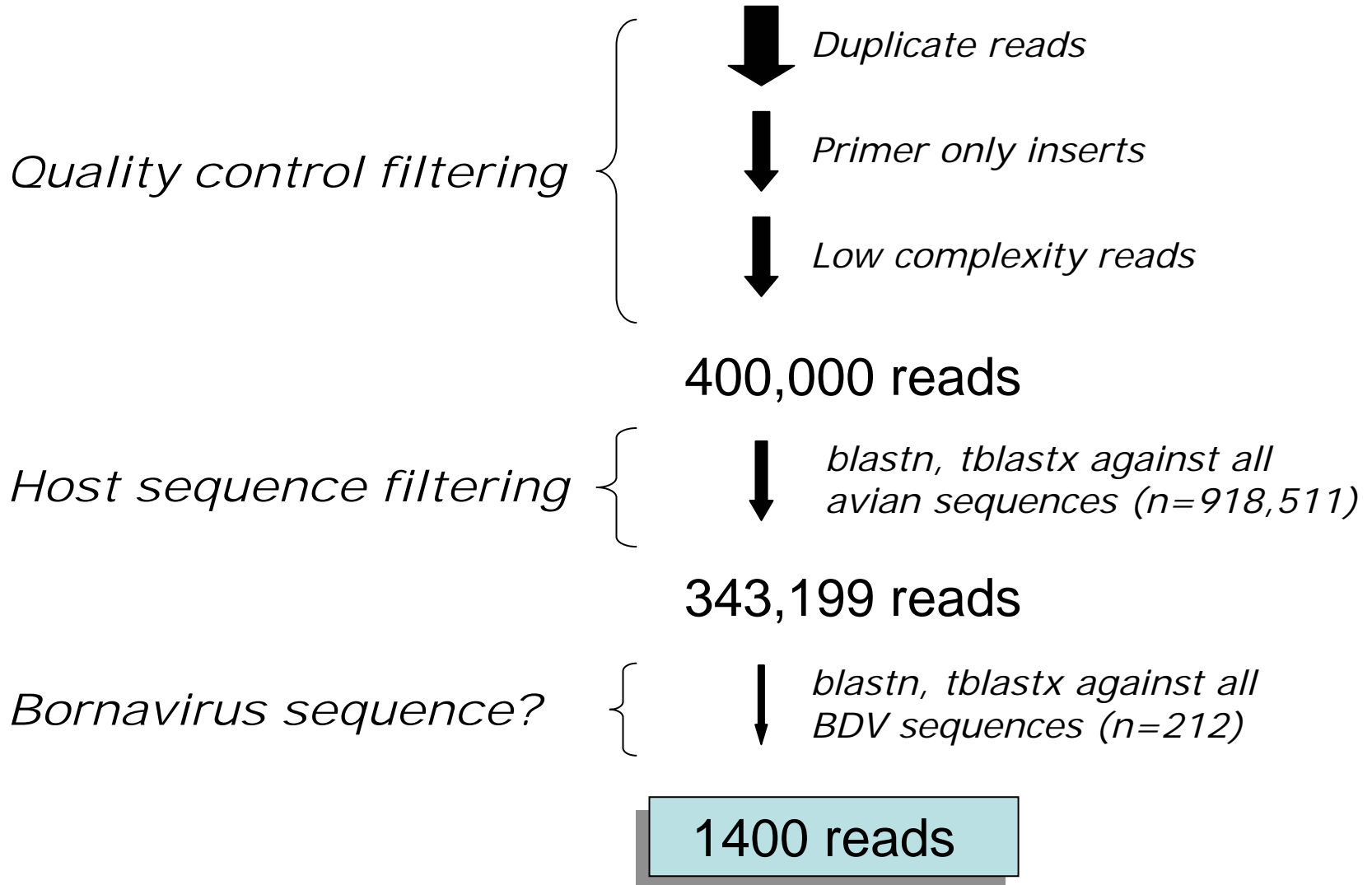


1000 molecules per ~ 1 um cluster
1000 clusters per 100 um square
40 million clusters per experiment

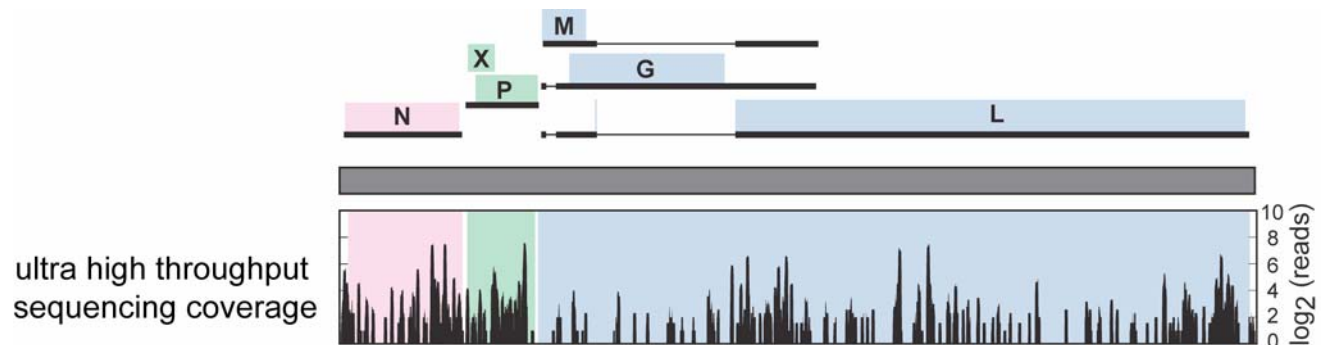
Deep sequencing of ABV+ crop tissue

Peter Skewes-Cox
(BMI rotation student)

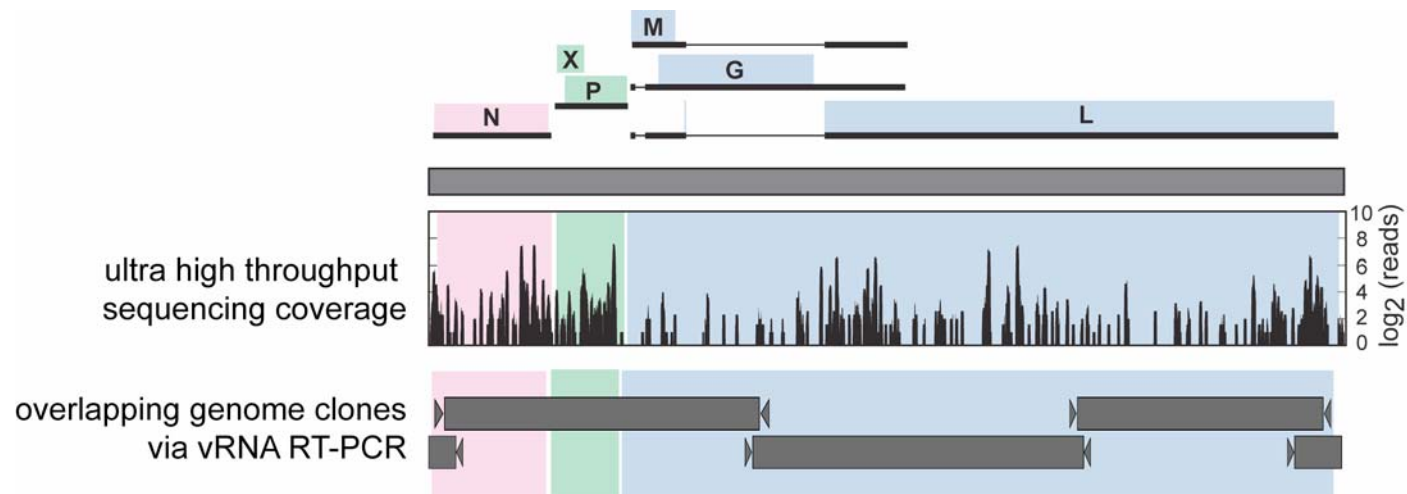
1.4million 33mer reads



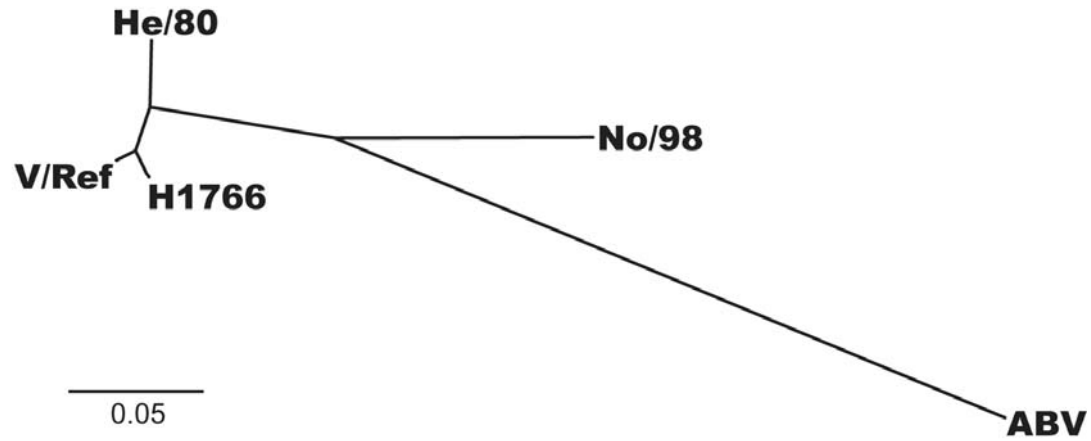
Deep sequencing reads span the bornavirus genome



Deep sequencing facilitates recovery of complete ABV genome sequence



ABV genome is highly diverged from BDVs



Summary: PDD study

1. We have identified a new clade of avian bornaviruses in cases of proventricular dilation disease of parrots.
2. We have found these avian bornaviruses are highly diverged from previously identified isolates *AND* each other.
3. Recovery of complete ABV genome sequence from PDD+ tissue demonstrates that the Virochip and RT-PCR assays accurately reflect the presence of a virus in these specimens.

Unresolved...

*Does ABV cause PDD?
or is it merely a bystander??*

1. *PDD case/control study:*
Is ABV infection associated with PDD?

- **Independent set of 21 additional case/control specimens**
Clinical status blinded until ABV analysis is completed

Yes!

	cases	controls	totals
ABV PCR ⁺	5	0	5
ABV PCR ⁻	2	14	16
totals	7	14	21

P=0.01, Fisher's Exact Test

2. PDD outbreak investigation-- A window on the natural history of acute ABV infections

Setting: CA breeder
100+ birds outdoors, 40+ indoors

Early July:
outdoor bird ('Kiwi') sick
v. thin, dropping weight, passing undigested seeds

- *Vet recommends isolation, meds*
- *Kiwi is brought indoors for treatment*



Meanwhile in the same area....



(Hand feeding of
unweaned chicks)

And, as a favor to a friend, breeder is boarding 3 additional unweaned chicks....



2. PDD outbreak investigation-- timeline

necropsied, tested

QuickTime™ and a
TIFF (Uncompressed) decompressor
are needed to see this picture.

ABV2+

Breeder:



chicks sick

1 chick
near death

Jul.

Aug.

Sept.

Oct.

-----several bird deaths-----

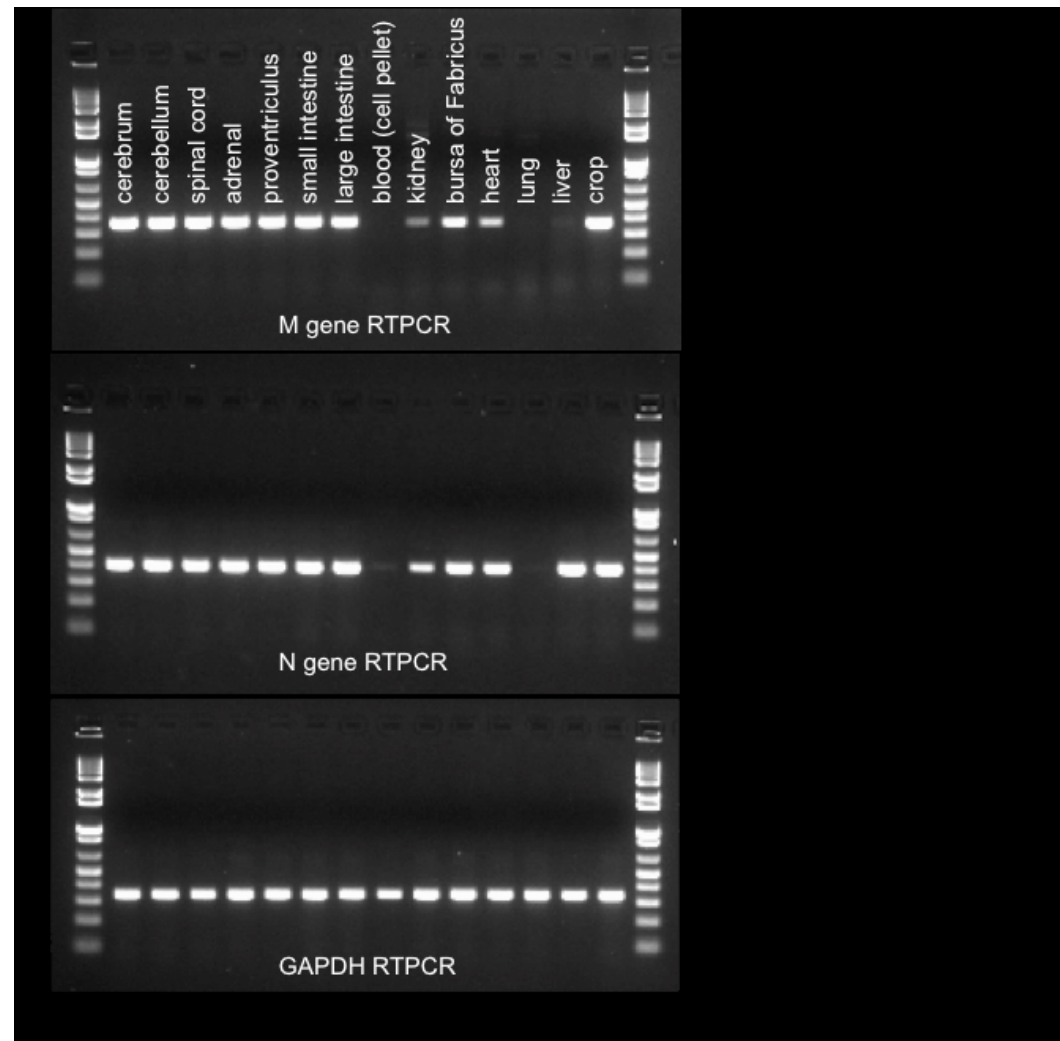
Friend:

chicks go back home
(no overt signs/symptoms)
indoors with 10 other birds

exposed
chicks now sick

1 chick dies

ABV RT-PCR analysis of necropsied tissues: reveals broad tropism





2. PDD outbreak investigation-- timeline

QuickTime™ and a
TIFF (Uncompressed) decompressor
are needed to see this picture.

necropsied, tested

ABV2+

Breeder:



chicks sick

-----several bird deaths-----

1 chick
near death

ABV testing indoor birds

Jul.

Aug.

Sept.

Oct.

Friend:

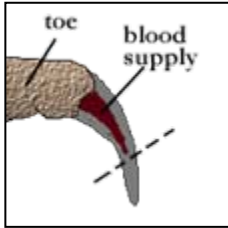
chicks go back home
(no overt signs/symptoms)
indoors with 10 other birds

exposed
chicks now sick

1 chick dies

Breeder 1: who else harbors ABV?

**46 birds sampled: all from indoors, potentially exposed to index case
(processed in order, lowest to highest exposure)**



Blood sample



Cloacal swab



- ABV N RTPCR
- ABV M RTPCR

Blood: only 2 positives detected

1 from 'low exposure' group, but feather picker with dermatitis (like index case)

1 from a bird that was briefly exposed to index case

None of these birds were showing classic PDD signs!

Cloacal swabs: 12 positives detected

2=same birds as above that were positive by blood test

2=very sick and subsequently euthanized (1 on site!)

4=african greys in 'low exposure' (1 very thin)

4='low exposure' (3 cockatoos and a macaw)



2. PDD outbreak investigation-- timeline

QuickTime™ and a
TIFF (Uncompressed) decompressor
are needed to see this picture.

necropsied, tested

ABV2+

Breeder:



chicks sick

-----several bird deaths-----

1 chick
near death

ABV testing indoor birds
12/46 ABV2+!

Jul.

Aug.

Sept.

Oct.

Friend:

chicks go back home
(no overt signs/symptoms)
indoors with 10 other birds

exposed
chicks now sick

1 chick dies

chicks
euthanized

2 surviving
chicks
tested

ABV2+

ABV RTPCR on tissues of exposed chicks



chick 2:

Exposed as chick

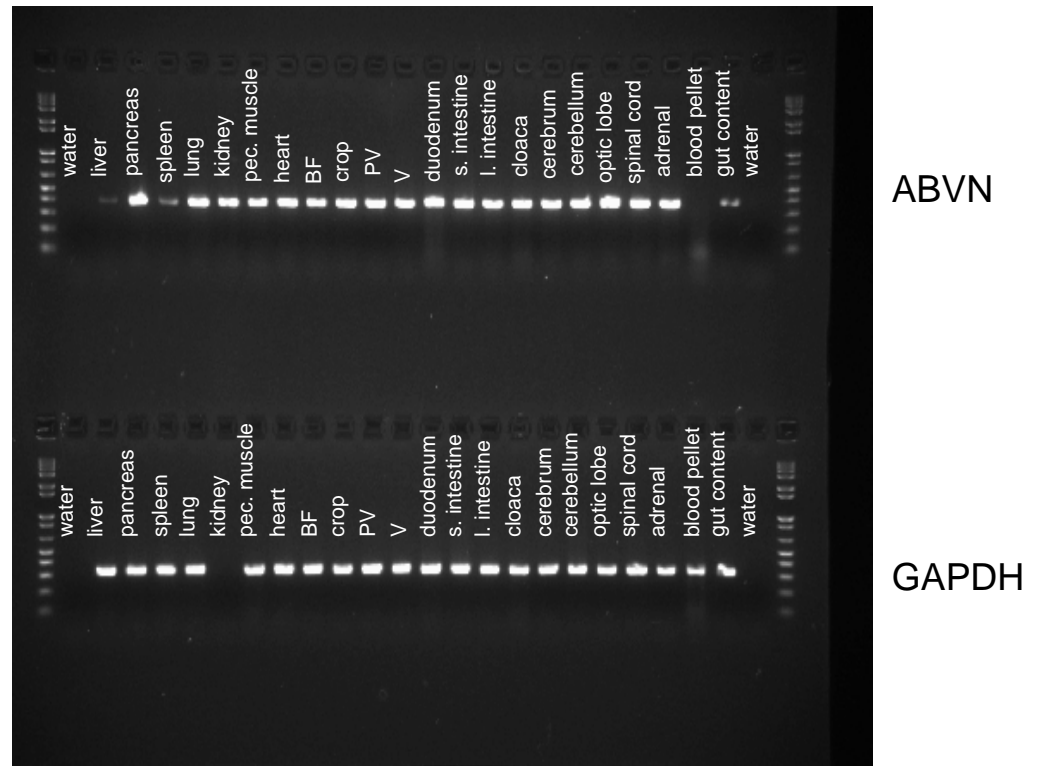
Sickened, appeared to recover

chick 3:

Exposed as chick

(Nestmate to chick 2)

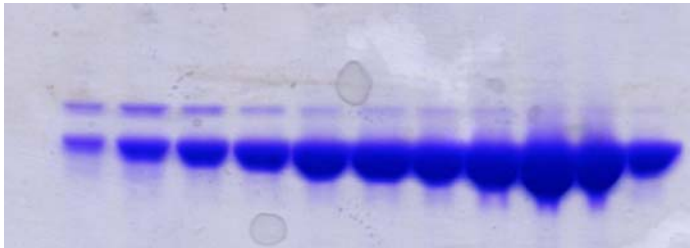
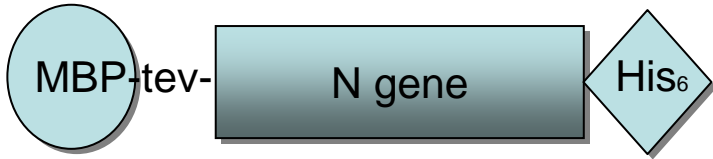
Sickened, still symptomatic



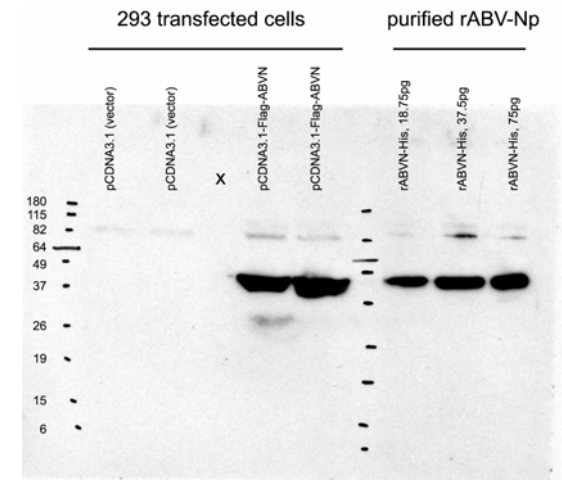
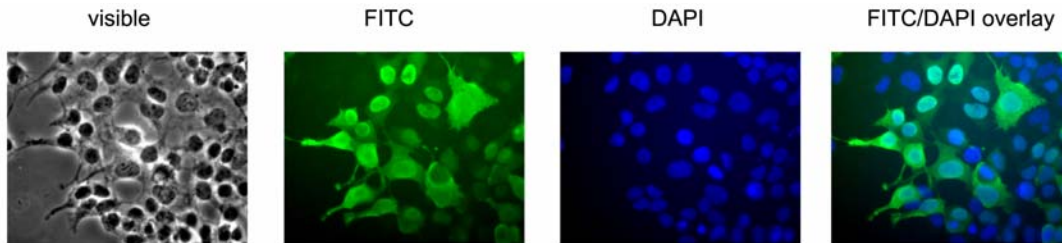
rProtein expression of antigenic ORFs

(Alexander Greninger)

Progress: nucleocapsid expression



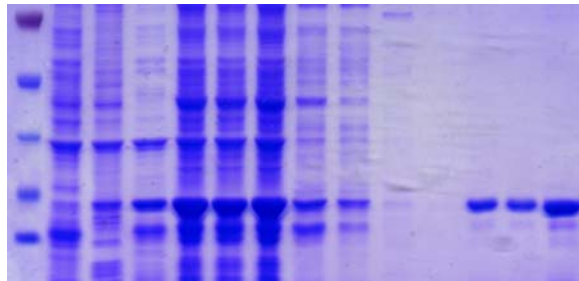
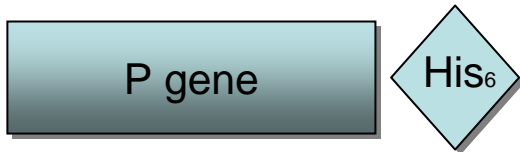- Expresses well
- Soluble
- Binds MBP, elutes well with TEV cleavage
- Purified by sizing column
- pAbs generated, work well in westerns, IFA



rProtein expression of antigenic ORFs

(Alexander Greninger)

Progress: phosphoprotein expression



- Expresses well
- Soluble
- Binds Nickel column well
- Purified by sizing column
- pAbs generated

Western blot on tissues of exposed chicks



chick 2:

Exposed as chick

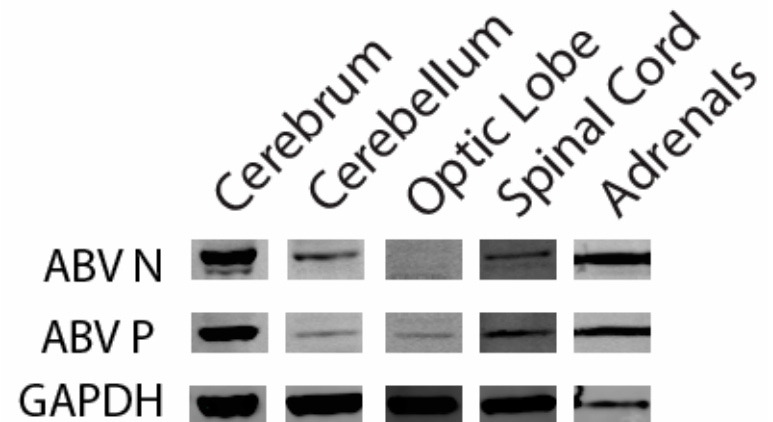
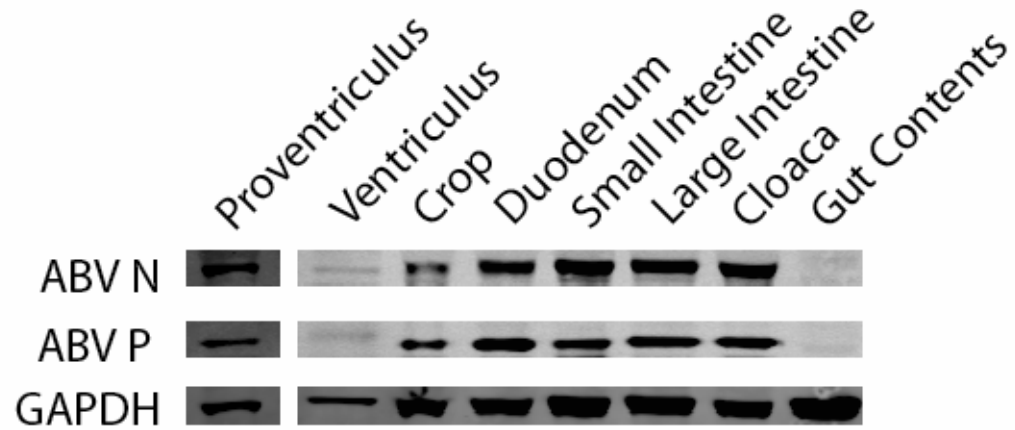
Sickened, apparently recovered

chick 3:

Exposed as chick

(Nestmate to chick 2)

Sickened, still symptomatic





2. PDD outbreak investigation-- timeline

QuickTime™ and a
TIFF (Uncompressed) decompressor
are needed to see this picture.

necropsied, tested

ABV2+

Breeder:



chicks sick

-----several bird deaths-----

1 chick
near death

ABV testing indoor birds
12/46 ABV2+!

Jul.

Aug.

Sept.

Oct.

Friend:

chicks go back home
(no overt signs/symptoms)
indoors with 10 other birds

exposed
chicks now sick

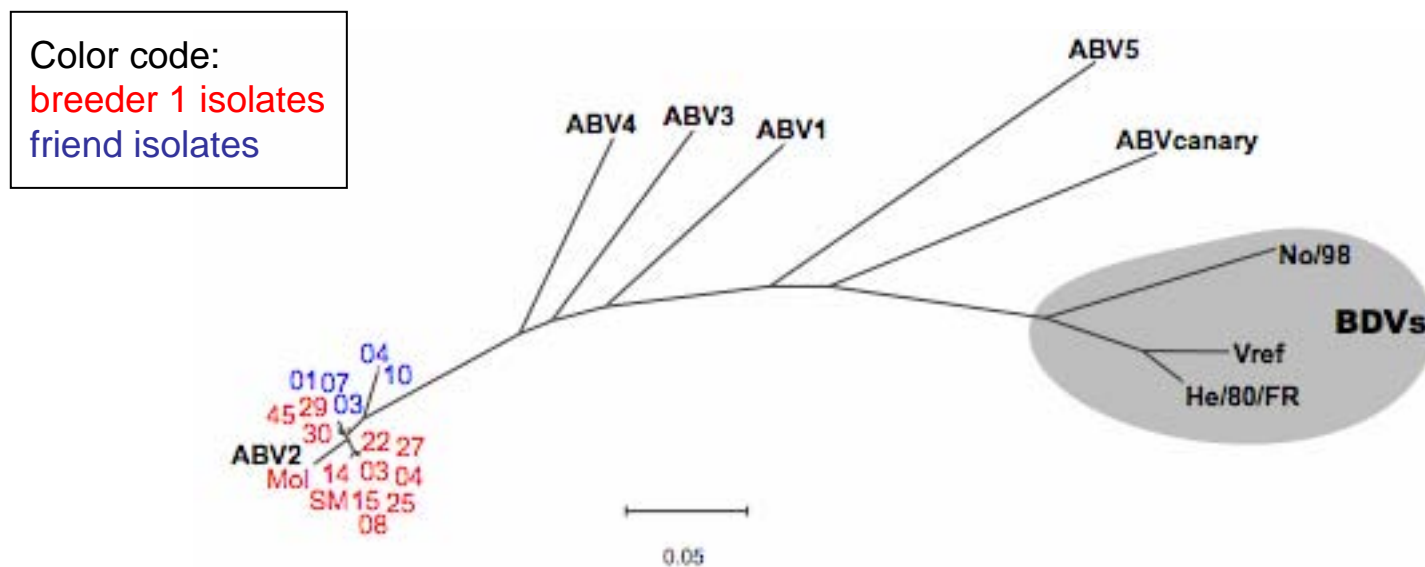
1 chick dies

chicks
euthanized **8/10**

2 surviving
chicks
tested
ABV2+

ABV testing
indoor birds
ABV2+

Confirming transmission, all ABV isolates recovered in outbreak are virtually identical



Partial ABVN gene nucleotide sequence phylogeny

PDD outbreak: summary

1. A single isolate of ABV2 linked to outbreak of PDD cases
2. Incubation time 2-4 weeks before PDD symptoms develop
3. Multiple tissues enriched for signs of ABV infection

3. ABV challenge study: approaching Koch's postulates

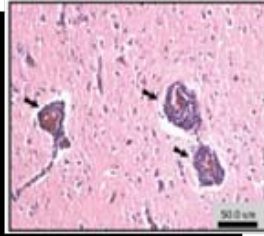


Can experimental exposure to ABV confer PDD?

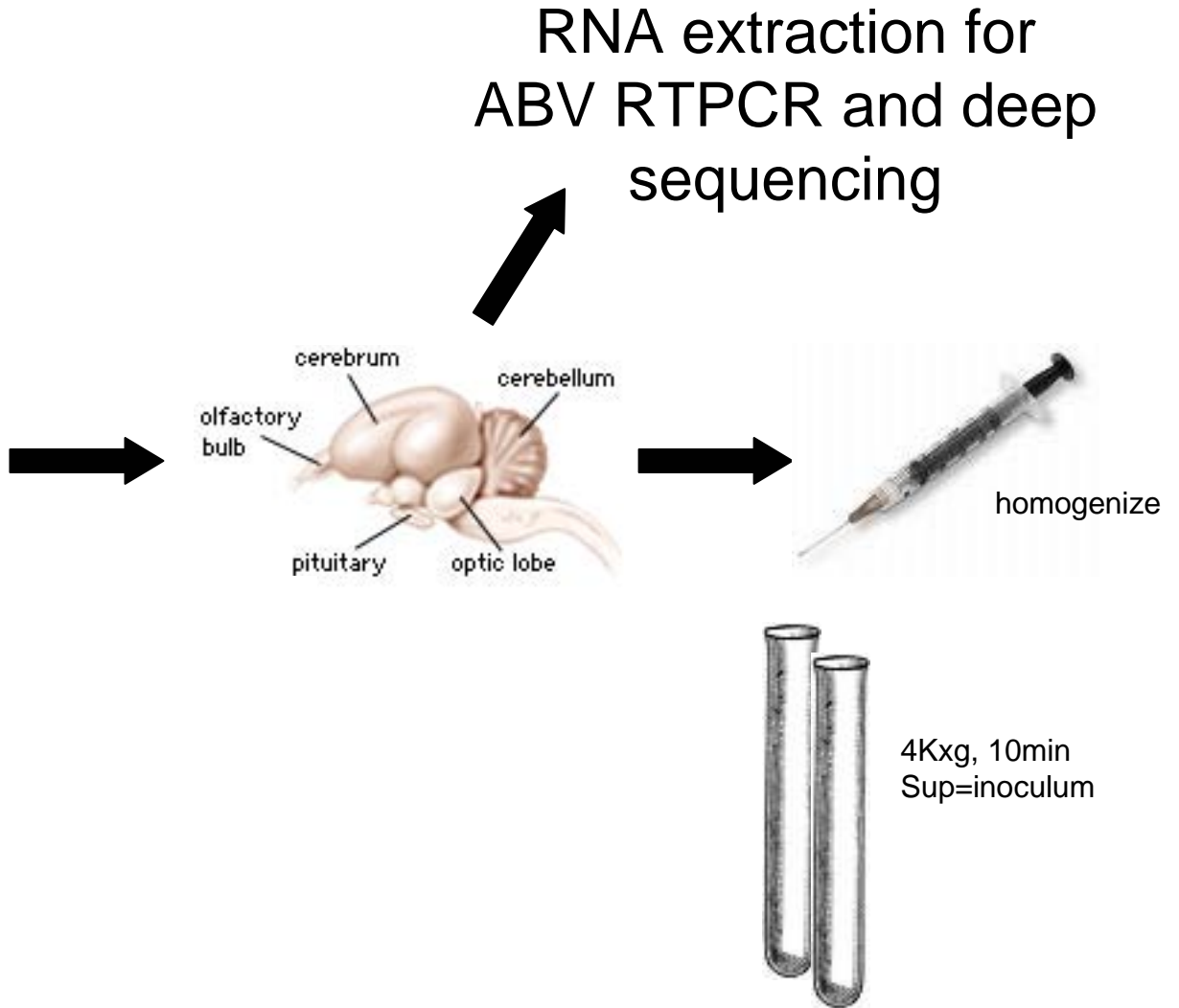
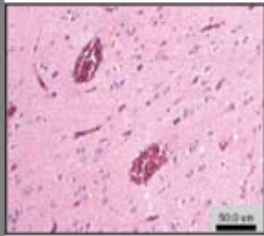
with Ady Gancz & Avishai Lublin

ABV inoculum preparation

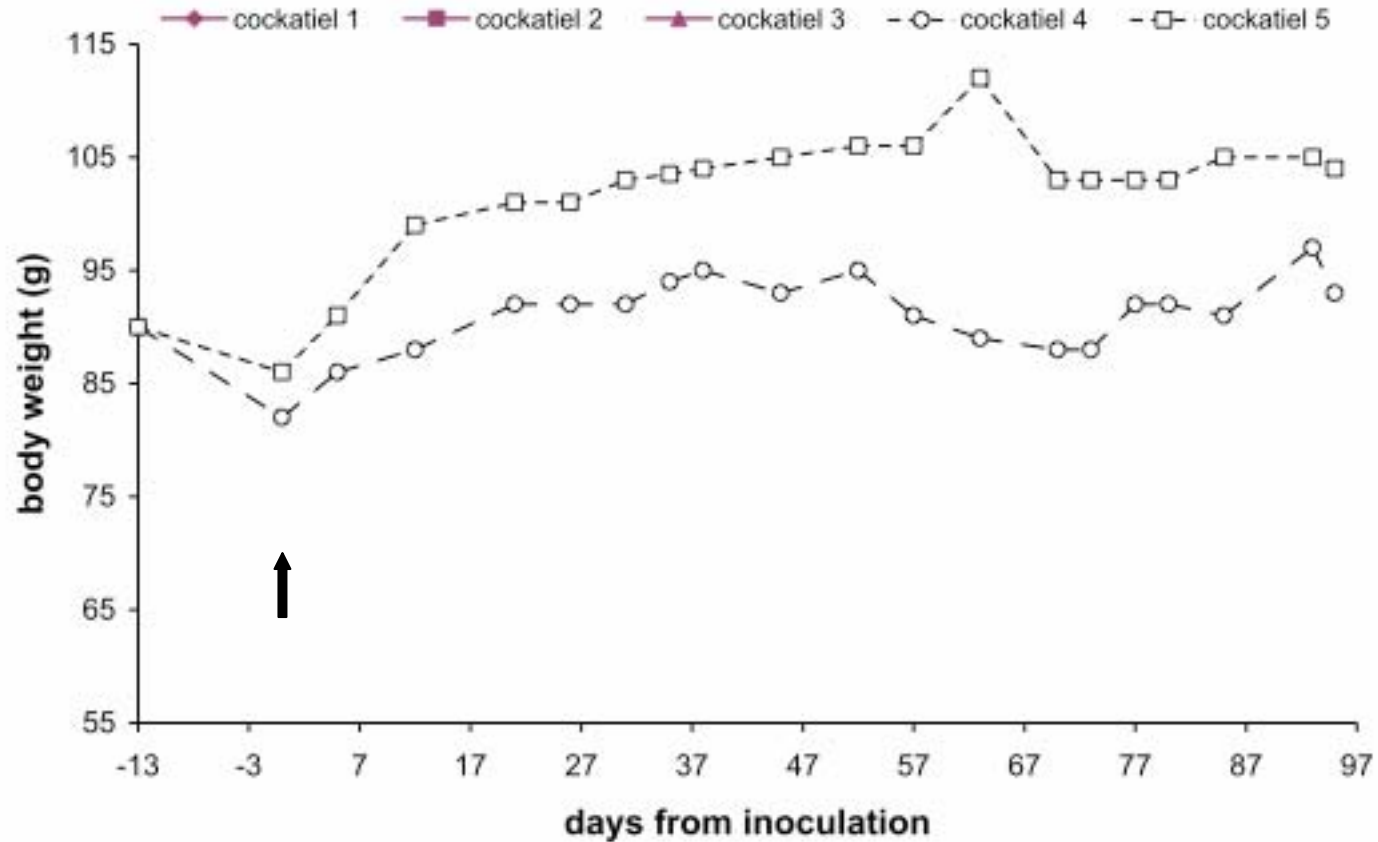
PDD+
African grey



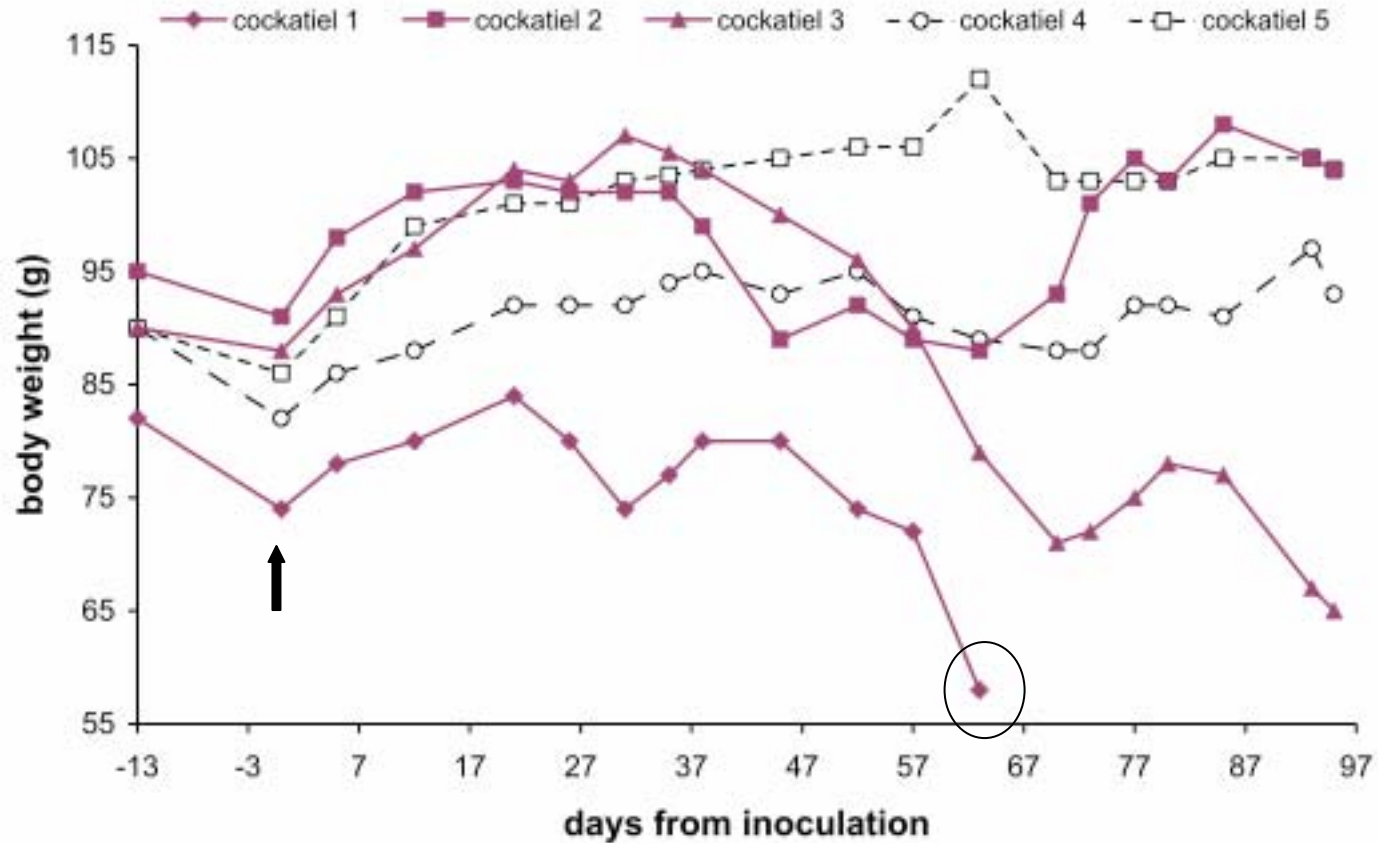
PDD-
African grey(?)



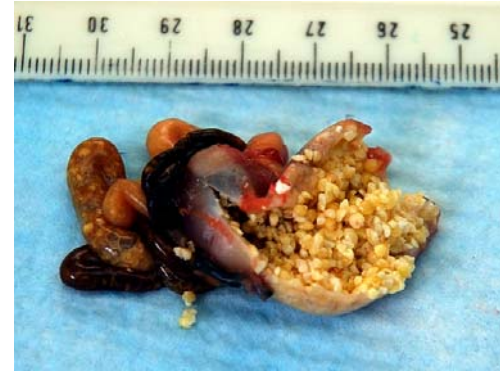
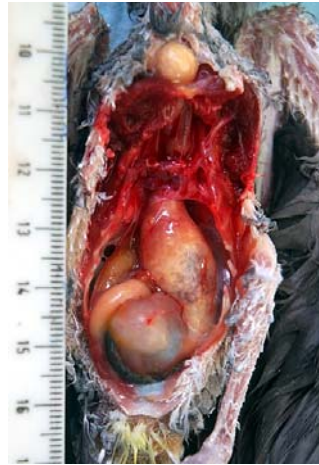ABV challenge: clinical observations



ABV challenge: clinical observations



ABV challenge: euthanized cockatiel



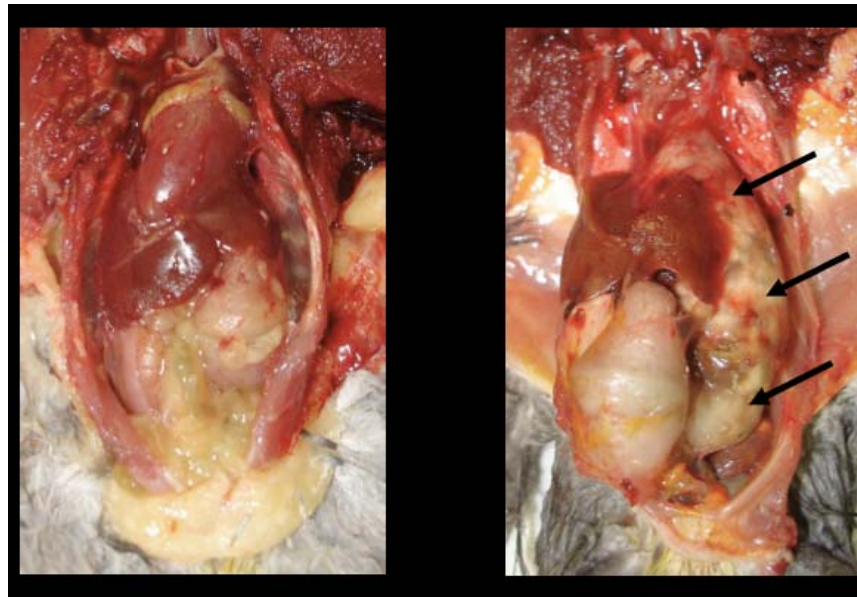
(Histology confirmed PDD+)

Pathology at study termination

Inoculum:

Sham

ABV+



3/3 ABV-inoculated are PDD+ on histology
2/2 sham-inoculated are PDD- on histology

RT-PCR results for challenge study

RTPCR for ABV and host RNA from matched necropsy tissues of inoculees

Tissue	ABV+ brain homogenate inoculees(n=3)	ABV- brain homogenate inoculees (n=2)
→ Brain	3	0
→ Spinal cord	1	0
Adrenal	0	0
→ PV/V	2	0
Liver	0	0
Lung	0	0
→ Heart	1	0
Pectoral muscle	0	0
skin	0	0

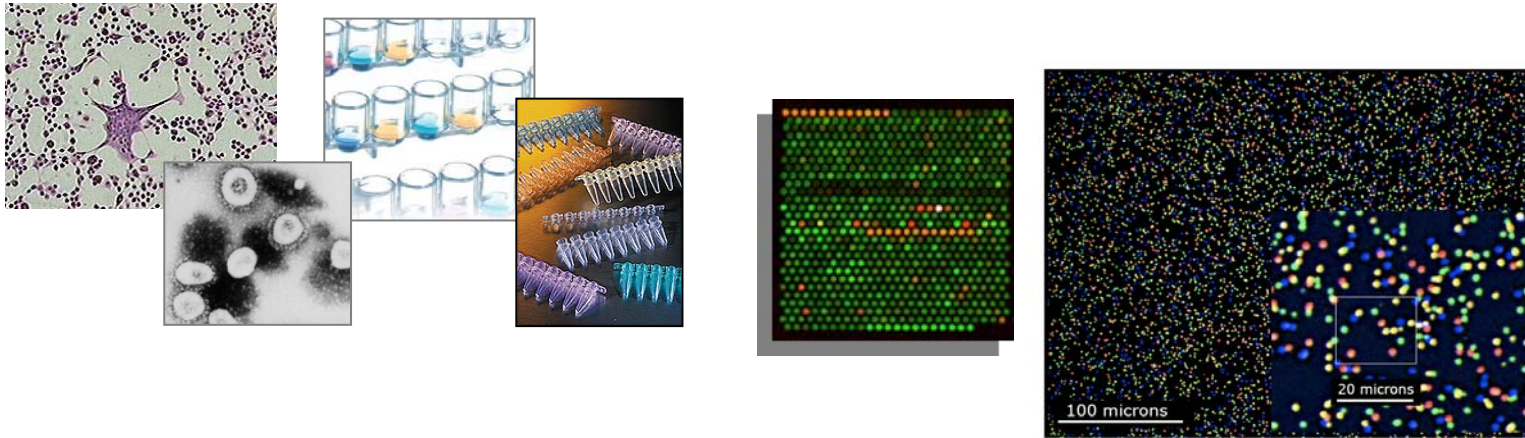
- *Recovered ABV products are 99-100% identical to ABV in brain inoculum.*
- *Deep sequencing of brain inoculum performed to screen for other viruses--
None of these were detected in any of the inoculees!*

ABV challenge study: summary

1. Experimental inoculation indicates ABV can transmit the pathology associated with PDD.
2. ABV infection can confers waxing/waning clinical signs.
3. Deep sequencing analysis of inoculum provides a route to begin to investigate causality in settings where virus is not culturable.

Future directions

Extend viral genomics studies



Utilize the combined power of conventional and viral genomics-based approaches to investigate 3 main types of clinical syndromes:

- Acute and chronic diseases with hallmarks of infectious origins
- Zoonotic diseases
- Outbreaks of illnesses of unknown cause

Future directions

Spin-off projects from the ABV discovery

Basic Biology:

- Develop in vitro culture system (live virus)
- Develop mini-replicon system
- Investigate viral lifecycle, pathology, mechanism of disease

Clinical side:

- Develop reliable RT-PCR diagnostic assay, ELISA
- Investigate epidemiology
- Explore prevention/treatment possibilities
 - Screening/Isolation?
 - Potential for protective vaccine?
 - Impact of anecdotal treatments (NSAIDs, amantadine)?

Human side:

- Explore possible links to parallel syndromes in humans:
 - Achalasia
 - Guillaine Barre syndrome?
 - Other?

Acknowledgements

Advisors

Don Ganem
Joe DeRisi

DeRisi lab-Vironauts

Dave Wang
Anatoly Urisman
Silvi Rouskin
Kael Fischer
Katherine Sorber
Charles Chiu
Peter Skewes-Cox
Chris Wen
Alex Greninger

Clinical collaborators

Homer Boushey
Pedro Avila

Susan Clubb

Ady Gancz

Jeanne Smith

Local breeders