LD, low dose
HD, high dose

Survival curve, LD USUV

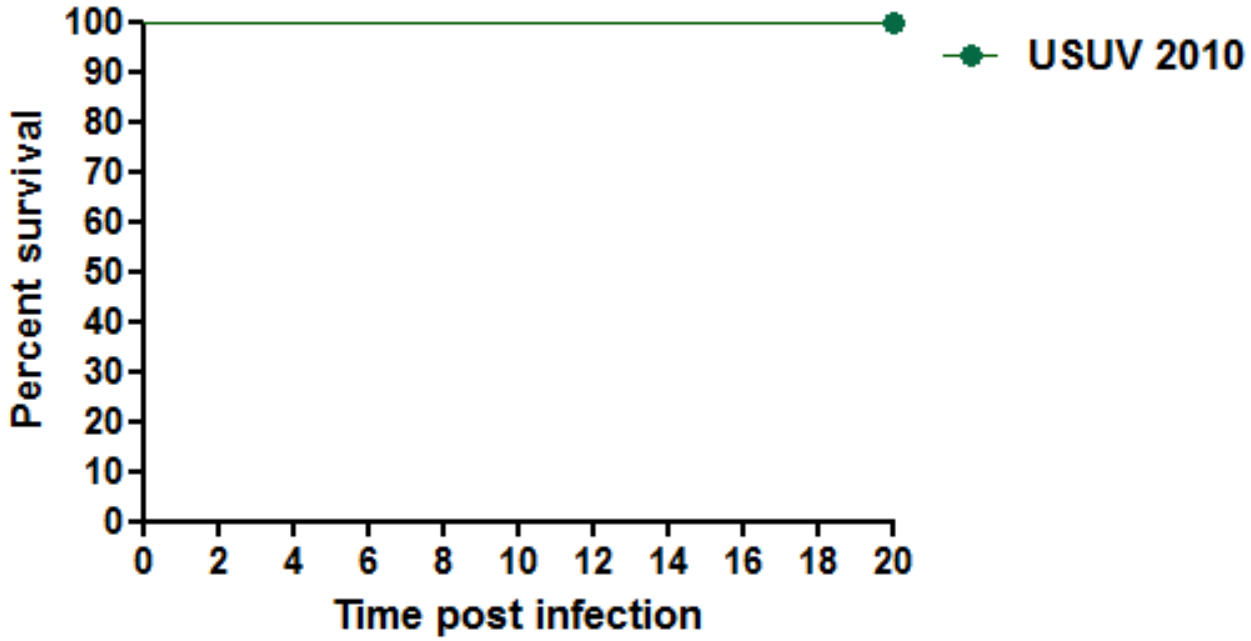

- **Mice poorly seroconverted to Usutu**

competent mice

LD, low dose
HD, high dose

Survival curve, HD USUV

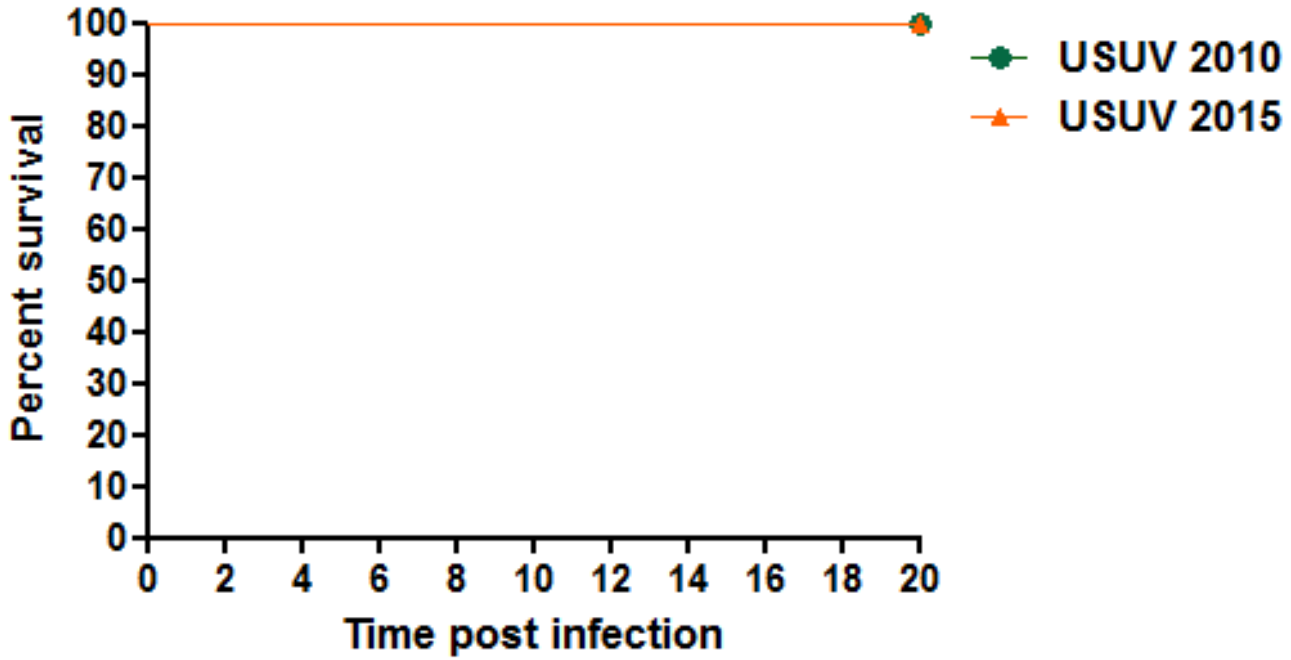

- **Mice poorly seroconverted to Usutu competent mice**

DISTRIBUZIONE DEL VIRUS NEI TESSUTI

- IP
- Euthanized starting from d3 pi
- qPCR and IHC from several tissues

- Murinized WNV
- NGS

WNV L1 15803
WNV L2 20168
WNV L1 20652 Livenza
USUV 2010

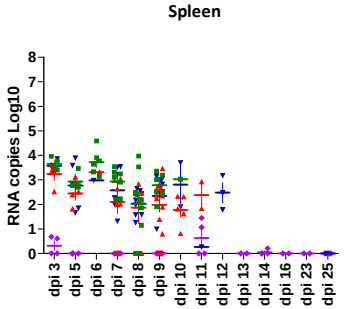

WNV L1 15803
WNV L2 20168
WNV L1 20652 Livenza
USUV 2010

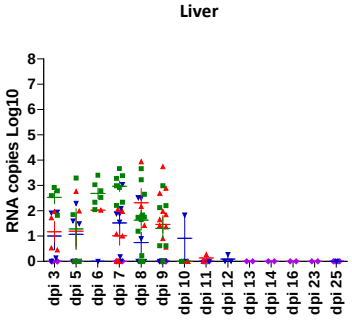

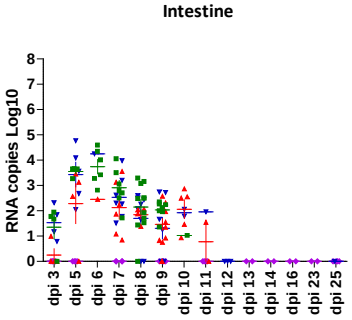

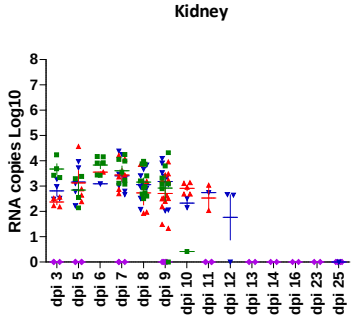

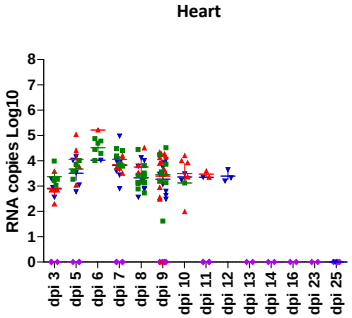

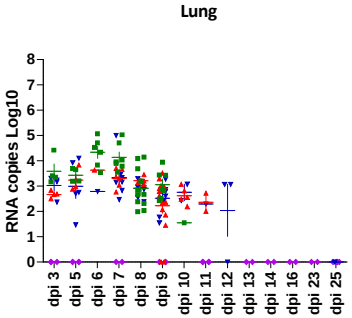

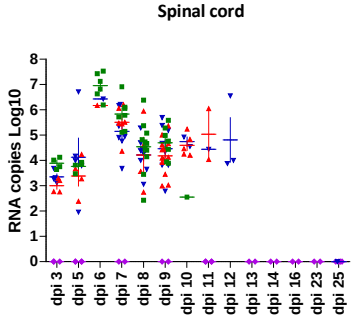

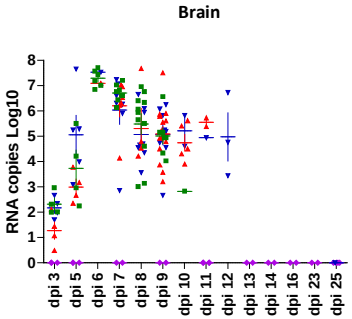

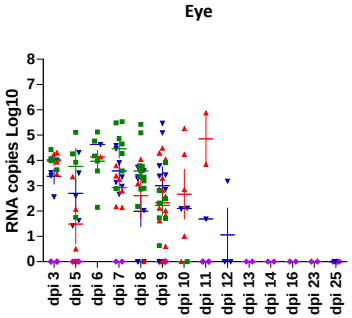

LIVENZA STRAIN
ID. 981-37
DAY 5 p.i.

SNC

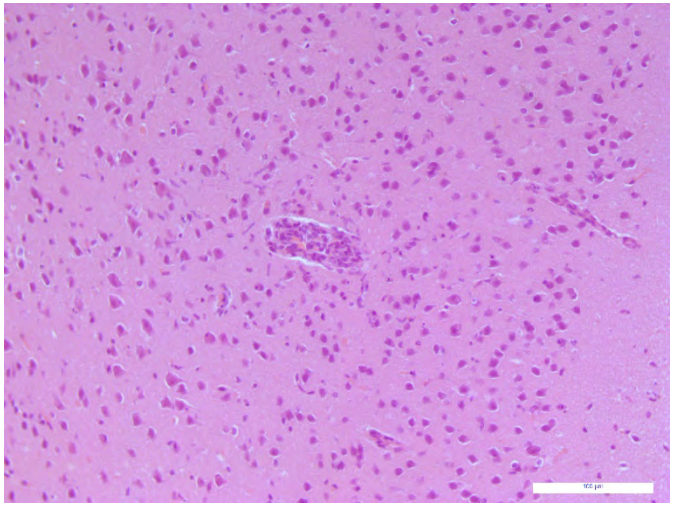

SNC: lymphoplasmocytic cuffing, EE.

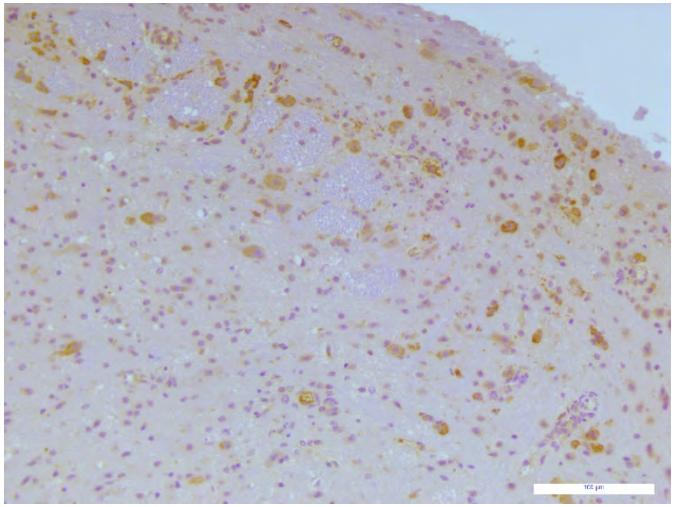

SNC: WNV protein was present in scattered neurons as cytoplasmic granular staining without visible pathology, IHC.

SPLEEN

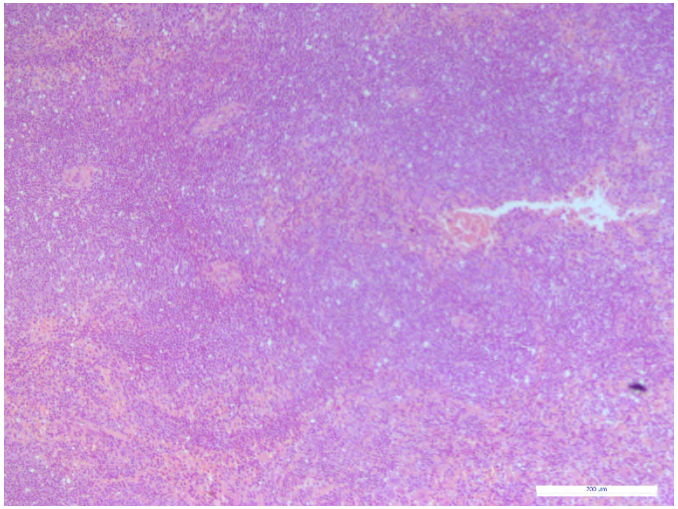

SPLEEN: Follicular marginal zone dendritic macrophages phagocytosis of lymphocytes and lymphocyte necrosis, EE.

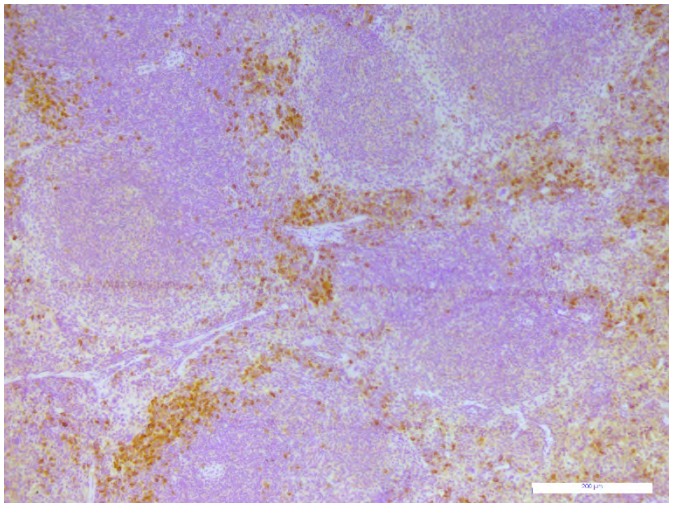

SPLEEN: Viral antigen is detected in dendritic cells/macrophages, IHC.

LIVENZA STRAIN
ID. 981-37
DAY 5 p.i.

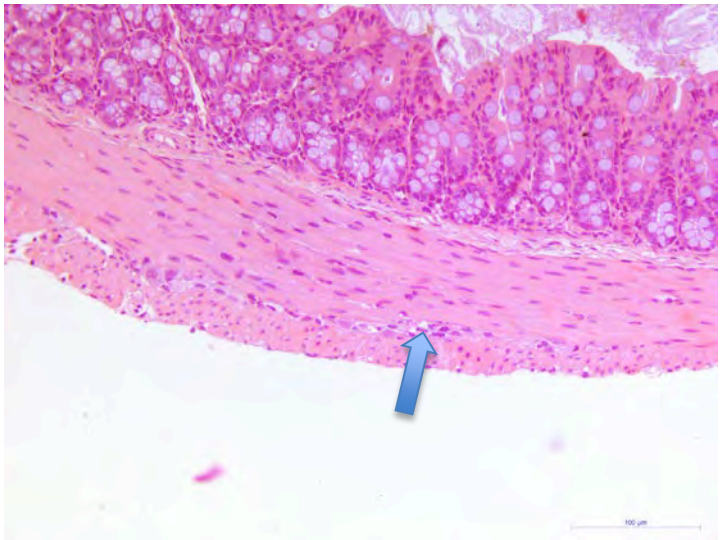

GUT

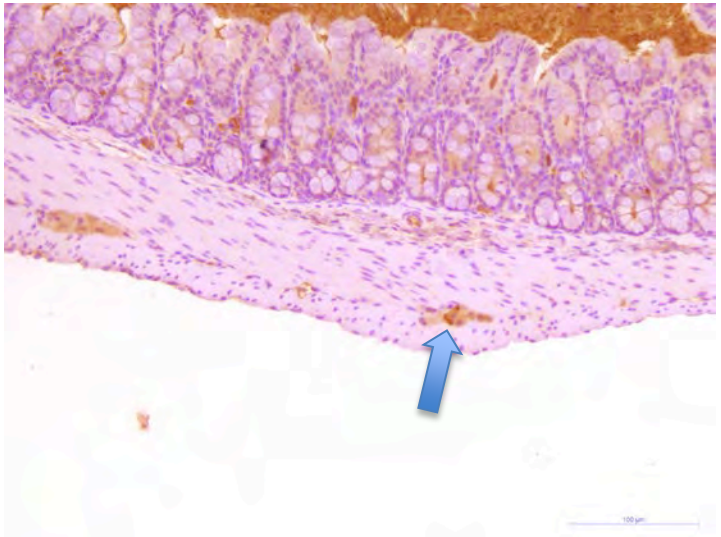

MYENTERIC PLEXUS: not visible lesions, EE.

MYENTERIC PLEXUS:Viral antigen is detected in neurons, IHC.

LIVENZA STRAIN
ID. 981-85
DAY 9 p.i.

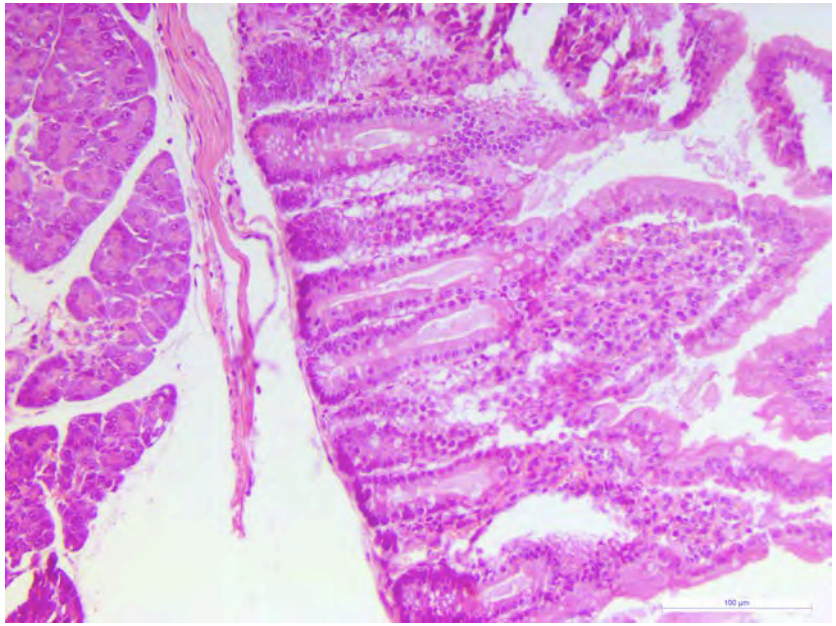

SMALL INTESTINE: mioderate infiltration of mononuclear cells and lymphocytes in the lamina propria, EE.

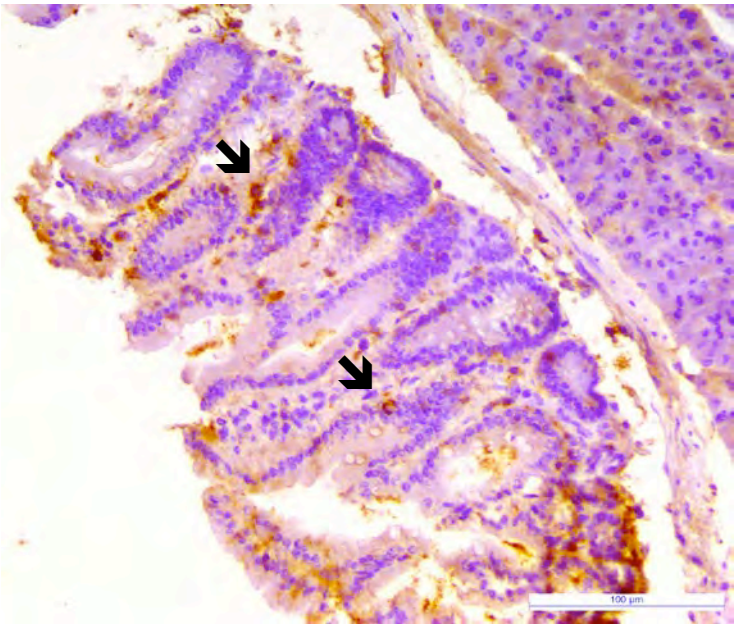

SMALL INTESTINE: viral antigens in mononuclear cells in the lamina propria (arrows), IHC.

Intestine (mucosa) destroyed

LIVENZA STRAIN
ID. 981-147
DAY 12 p.i.

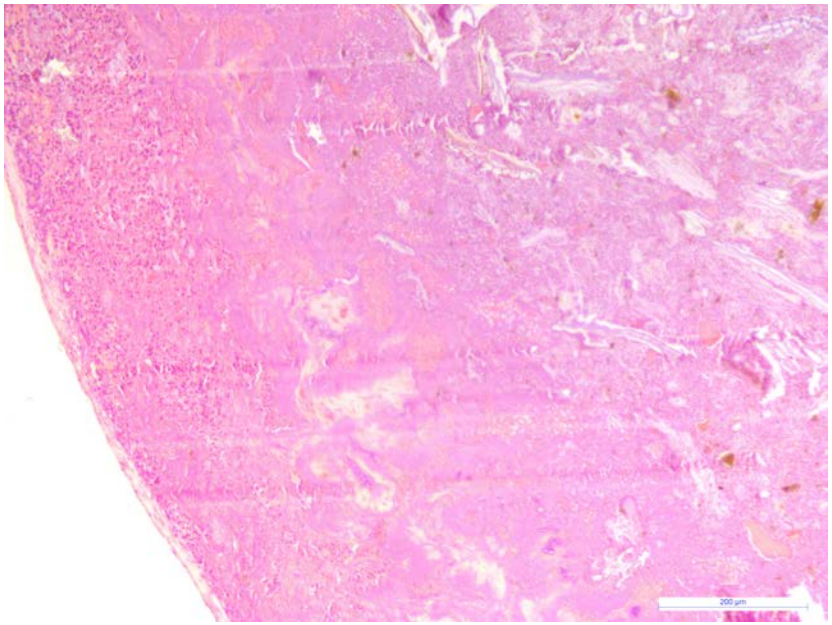

SMALL INTESTINE: severe mucosal injury with necrosis, EE.

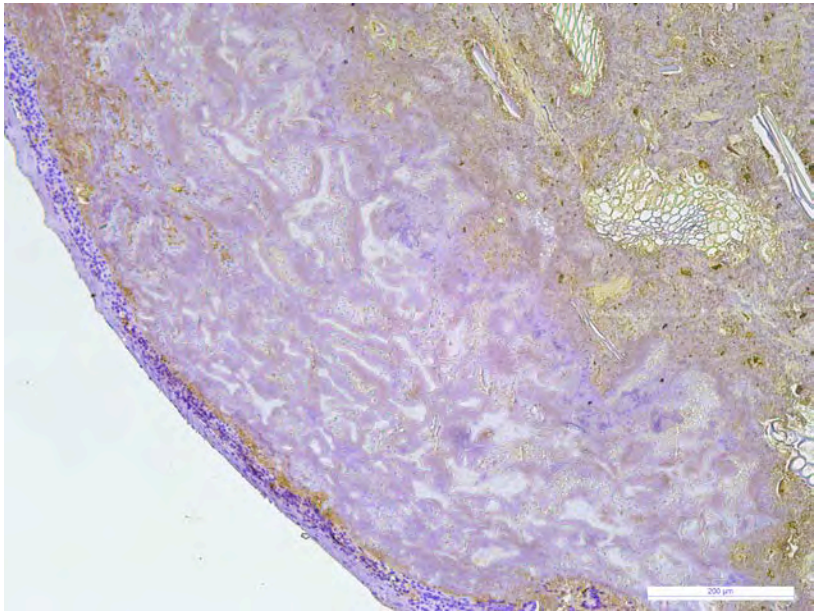

SMALL INTESTINE: WNV negative, the myenteric plexus was not appreciable, IHC.

15803 STRAIN
ID. 981-45
DAY 6 p.i.

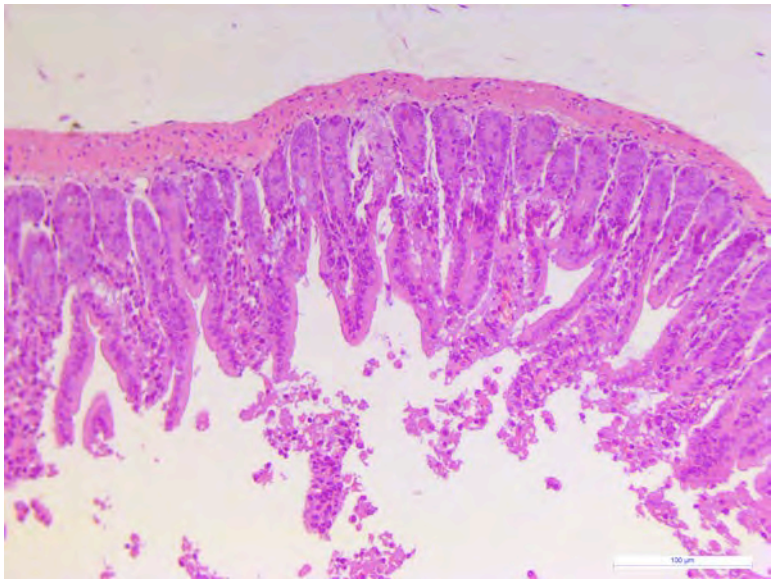

SMALL INTESTINE (duodenum): mild infiltration of mononuclear cells and lymphocytes in the lamina propria, EE.

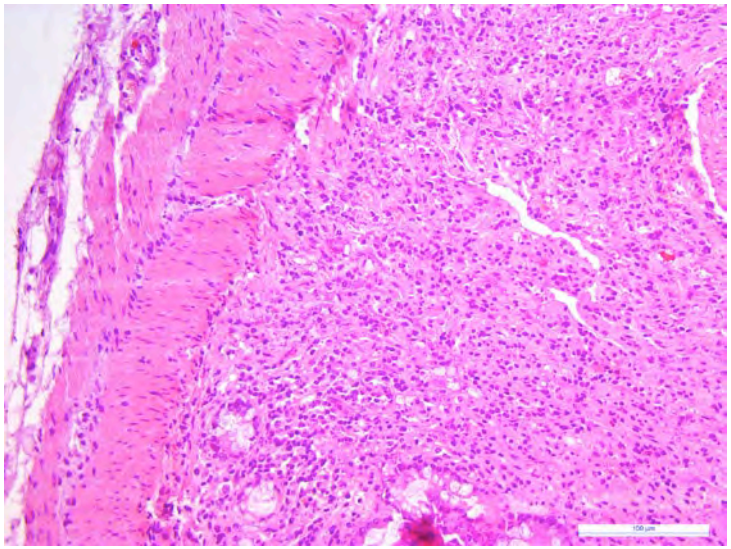

SMALL INTESTINE (digiunum): diffuse inflammatory villus fusion,EE.

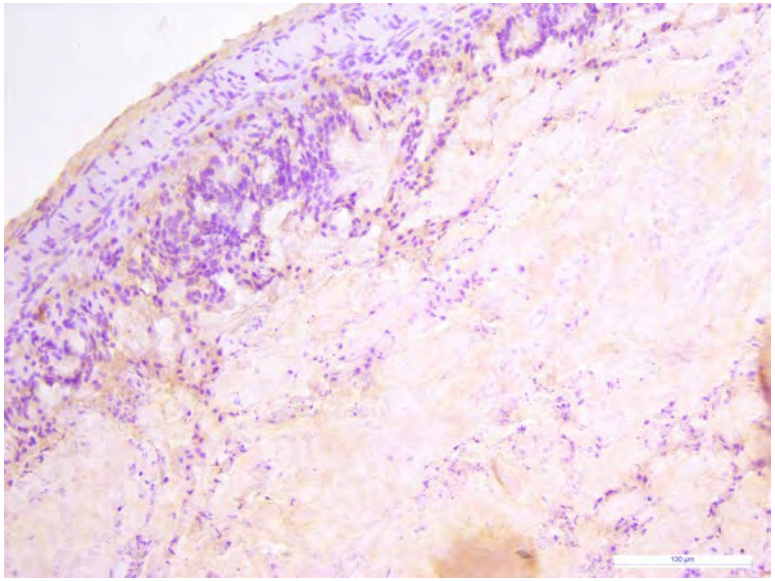

SMALL INTESTINE: WNV antigens was not detected,IHC.

15803 STRAIN
ID. 981-117
DAY 9 p.i.

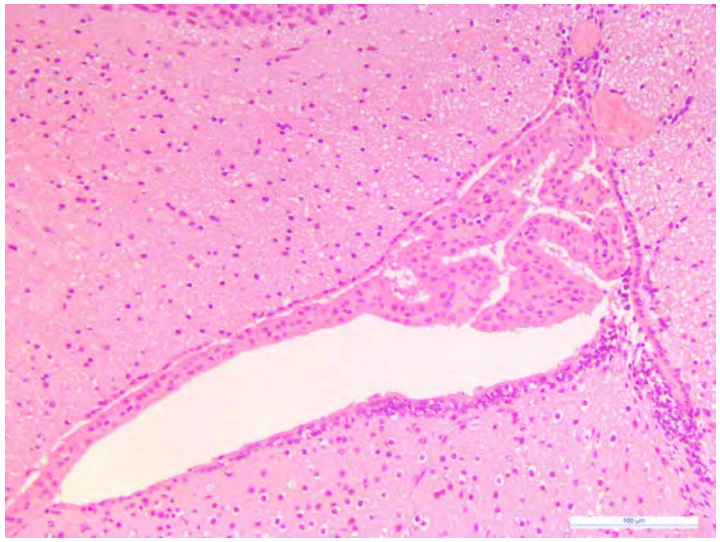

SNC:

Meningitis

Perivascular Cuffing

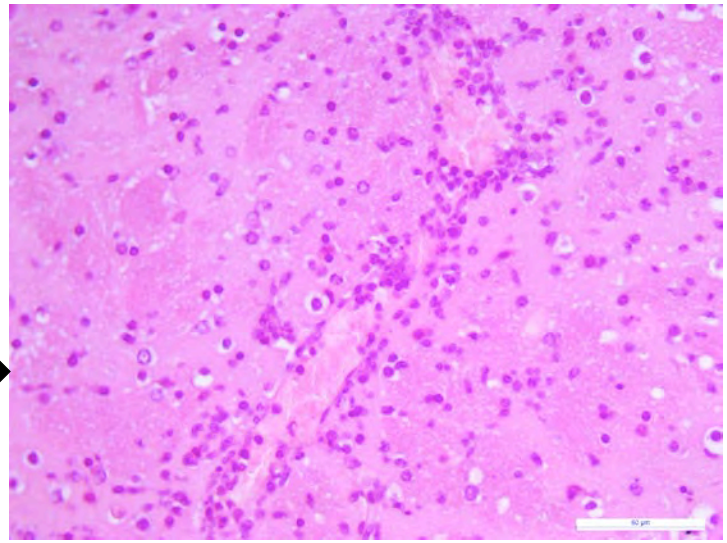

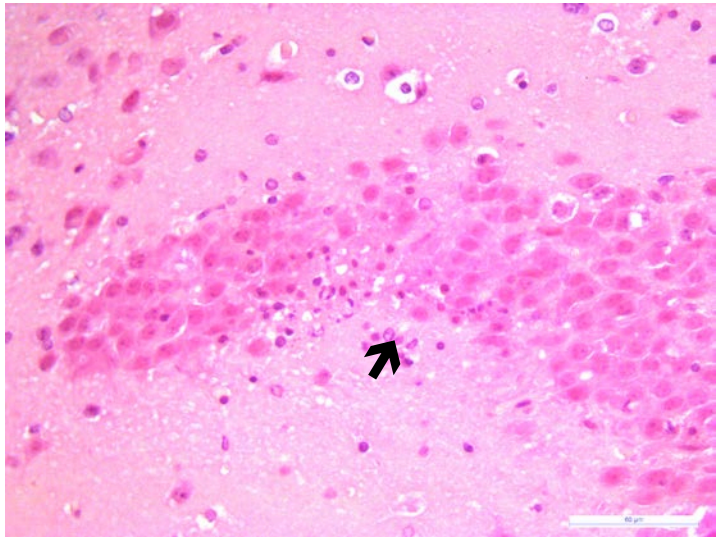

SNC-hippocampus (stratum granulosum): numerous apoptotic bodies (arrow), EE.

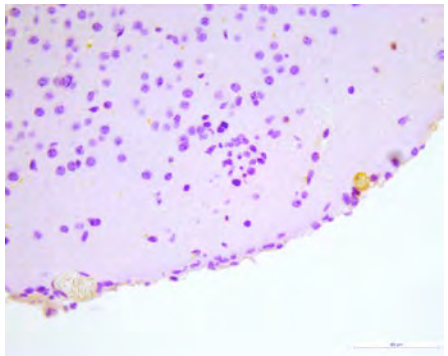

SNC: WNV antigens was not detected,IHC.

15803 STRAIN
ID. 981-117
DAY 9 p.i.

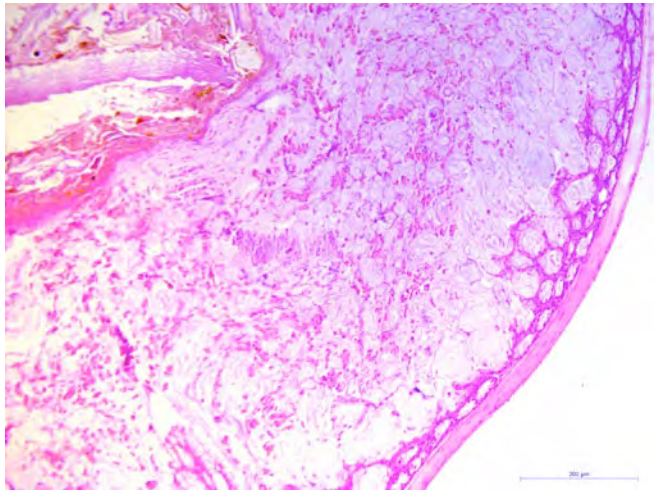

SMALL INTESTINE: shortned villi with mucosal degeneration and necrosis, EE.

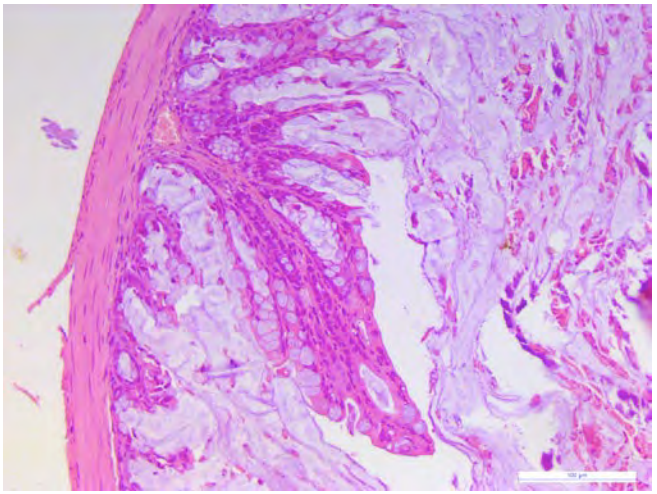

LARGE INTESTINE: mucus hypersecretion from necrotic intestinal tissues, EE.

20168 STRAIN
ID. 981-70
DAY 9 p.i.

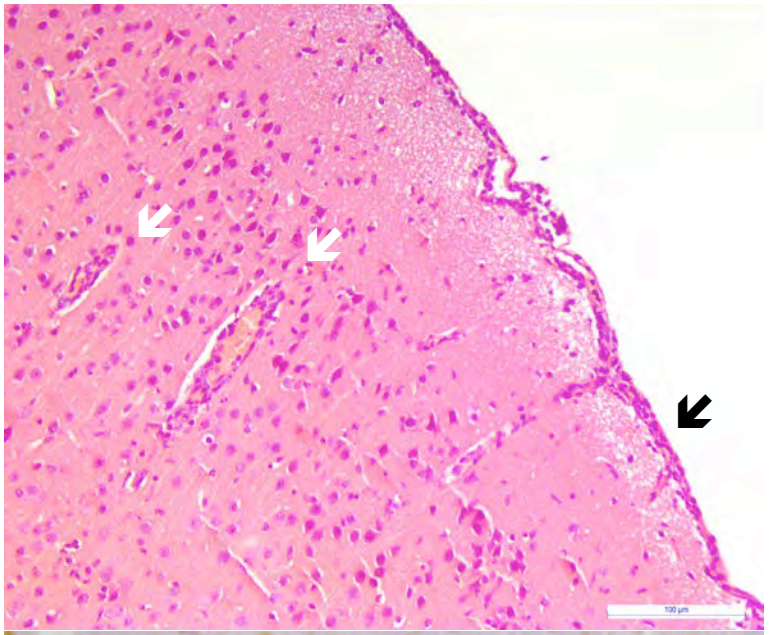

SNC: meningitis (black arrow), perivascular cuffing (white arrows), EE.

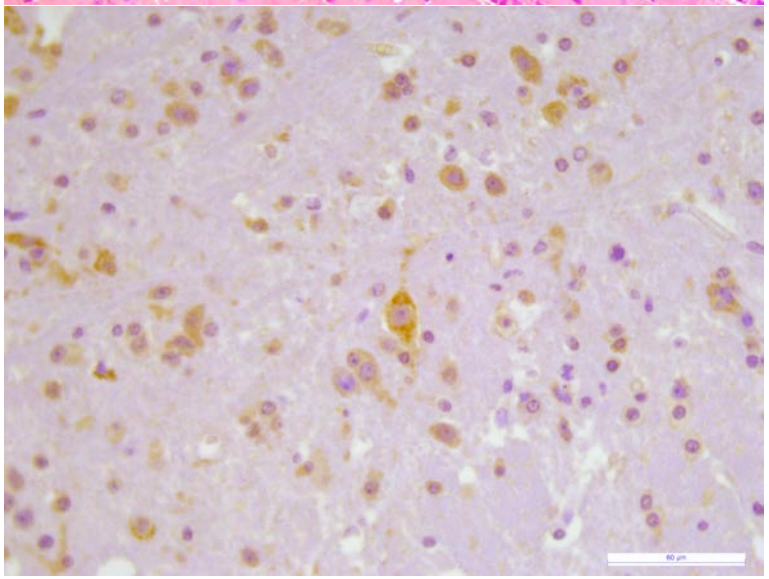

SNC: WNV antigens in neurons

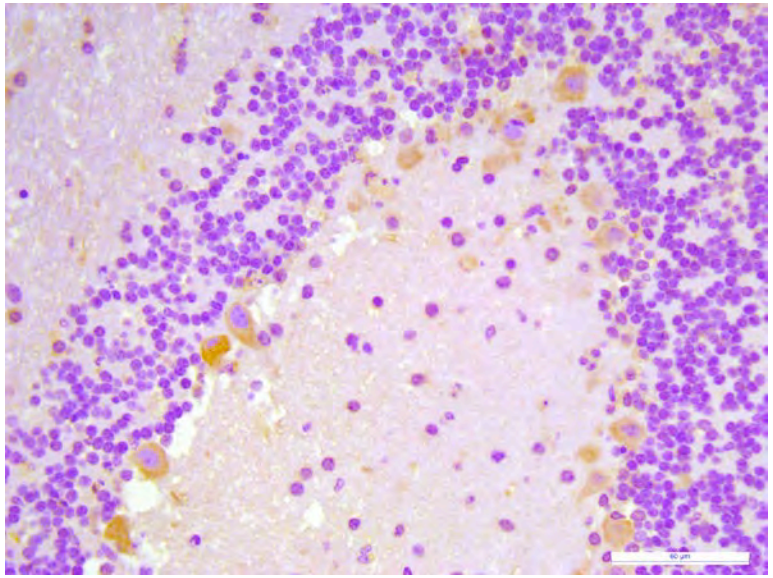

20168 STRAIN
ID. 981-140
DAY 11 p.i.

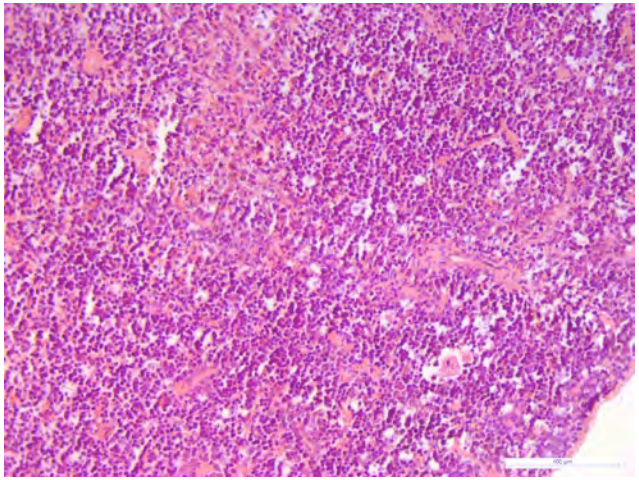

SPLEEN:moderate depletion of white pulp. Dendritic macrophages phagocytosis of lymphocytes (tingible body macrophages), EE.

🡐🡐

SPLEEN: WNV antigens present in some scattered macrophages, IHC.

🡒🡒

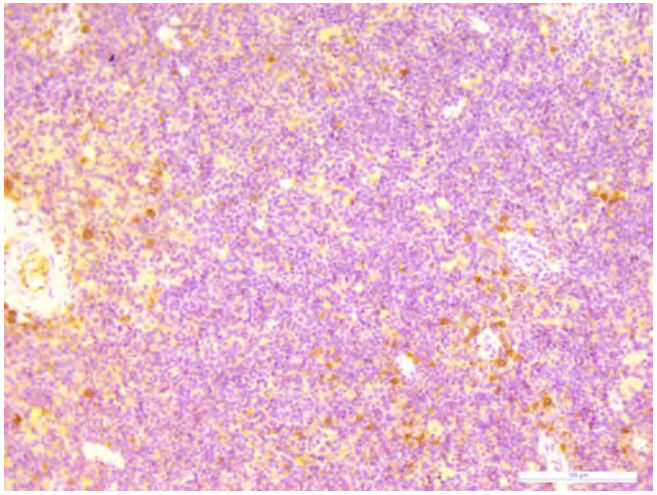

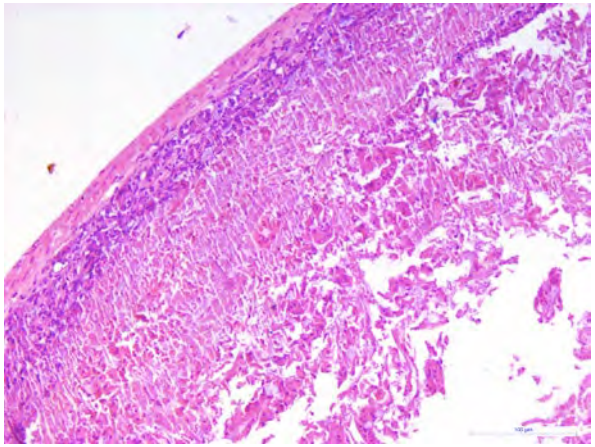

SMALL INTESTINE: shortned villi with mucosal degeneration and necrosis, EE.

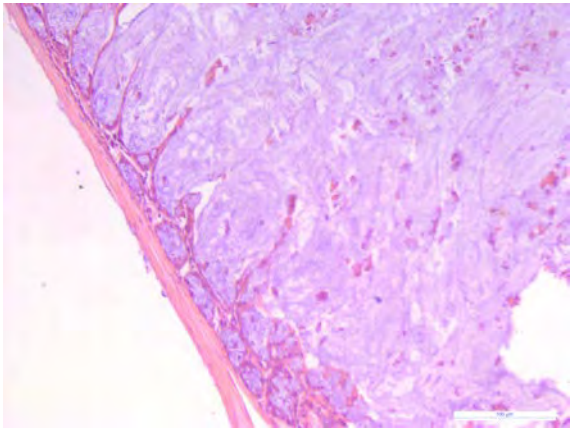

LARGE INTESTINE: mucosal degeneration with mucus hypersecretion, EE.

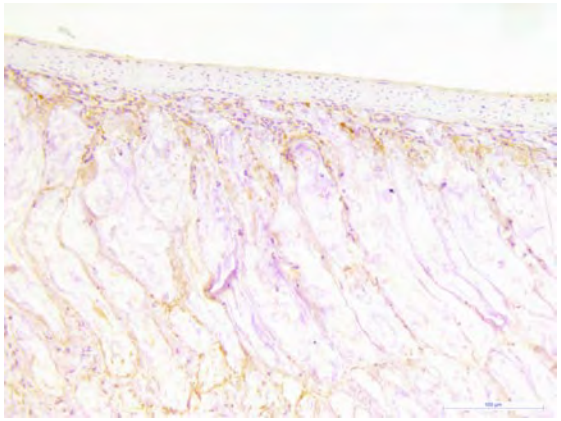

Intestine: no viral antigens were detected, IHC.

INTERAZIONE WNV/USUTU IN VIVO

Science

REPORTS

Cite as: S. V. Bardina *et al.*, *Science* 10.1126/science.aal4365 (2017).

Enhancement of Zika virus pathogenesis by preexisting antiflavivirus immunity

Susana V. Bardina,[1*] Paul Bunduc,[1*] Shashank Tripathi,[1,2*] James Duehr,[1*] Justin J. Frere,[1] Julia A. Brown,[1] Raffael Nachbagauer,[1] Gregory A. Foster,[3] David Krysztof,[3] Domenico Tortorella,[1] Susan L. Stramer,[3] Adolfo García-Sastre,[1,2,4,†] Florian Krammer,[1,†] Jean K. Lim[1,†]

[1]Department of Microbiology, Icahn School of Medicine at Mount Sinai, New York, NY, USA. [2]Global Health and Emerging Pathogens Institute, Icahn School of Medicine at Mount Sinai, New York, NY, USA. [3]American Red Cross, Gaithersburg, MD, USA. [4]Division of Infectious Diseases, Department of Medicine, Icahn School of Medicine at Mount Sinai, New York, NY, USA.

*These authors contributed equally to this work.

†Corresponding author. Email: adolfo.garcia-sastre@mssm.edu (A.G.-S.); florian.krammer@mssm.edu (F.K.); jean.lim@mssm.edu (J.K.L.)

Zika virus (ZIKV) is spreading rapidly into regions around the world where other flaviviruses, such as

, 2017

LD, low dose
HD, high dose

Survival curve, HD USUV 2010, challenge with HD WNV

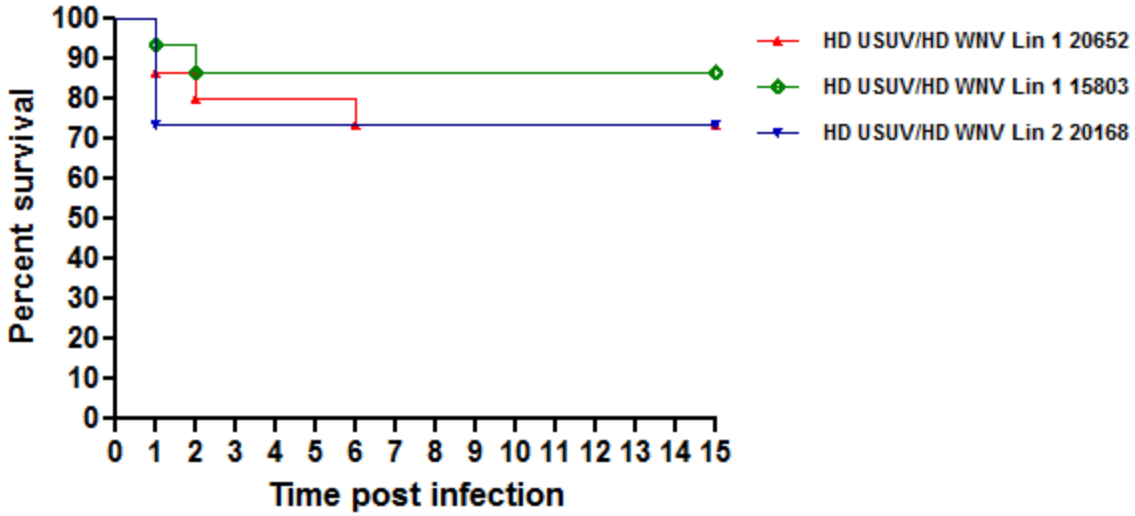

- **Mice poorly seroconverted to Usutu**

competent mice

Challenge

8453-12/17

D6 p.i.

(HD/HD, qPCR -, IHC-)

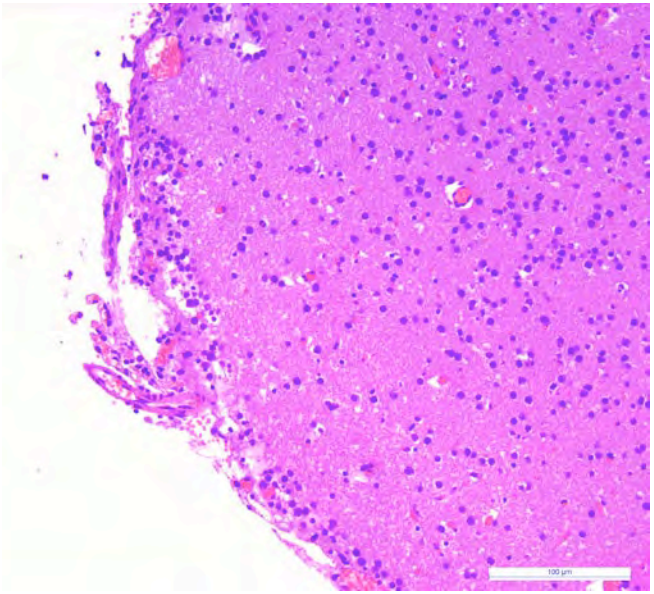

BRAIN: meningoencephalitis with hemorrage and necrosis, EE.

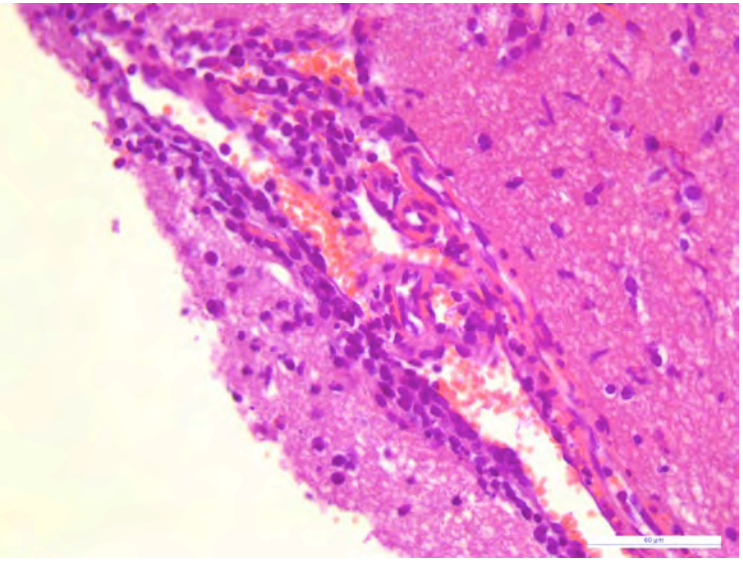

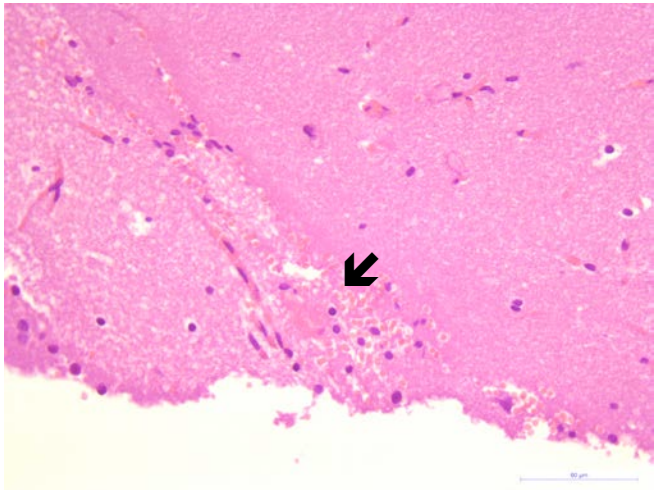

BRAIN: congestion and microhemorrhages (black arrow) and hemorrhage (bleu arrows) in the parenchyma, EE.

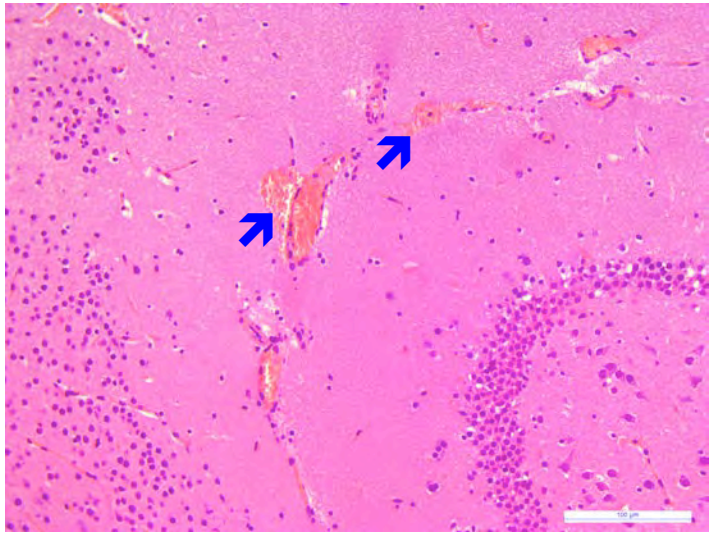

Challenge

8453-12/17
D6 p.i.

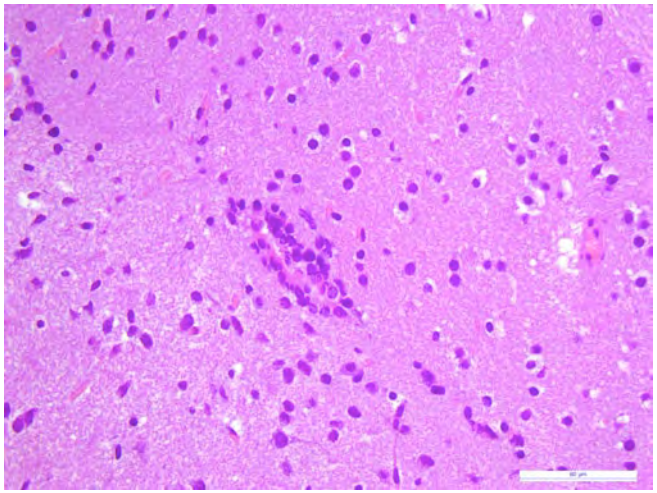

BRAIN: lymphocytic perivascular cuffing, EE.

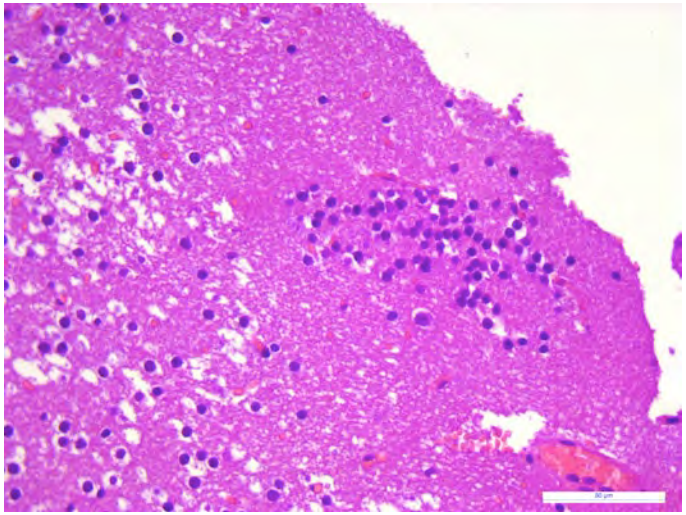

BRAIN:
microglial cells
infiltrates, EE.

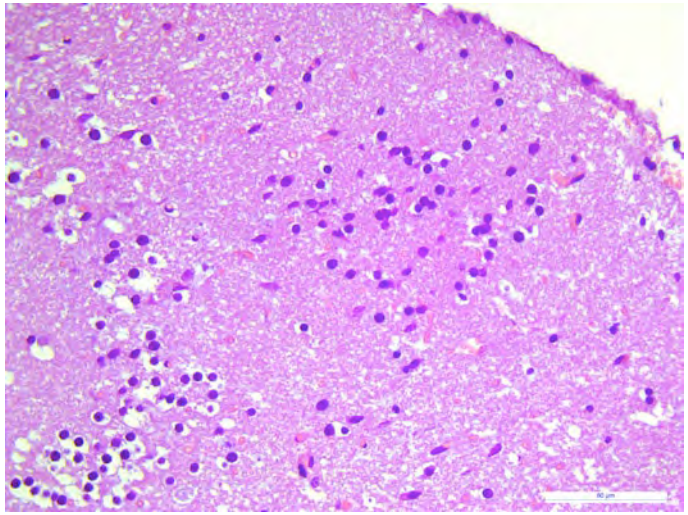

Challenge

8453-12/17
D6 p.i.

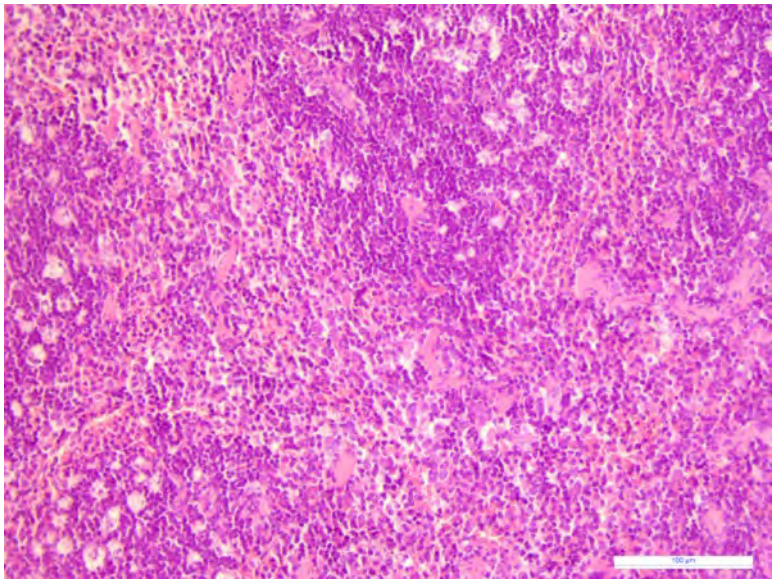

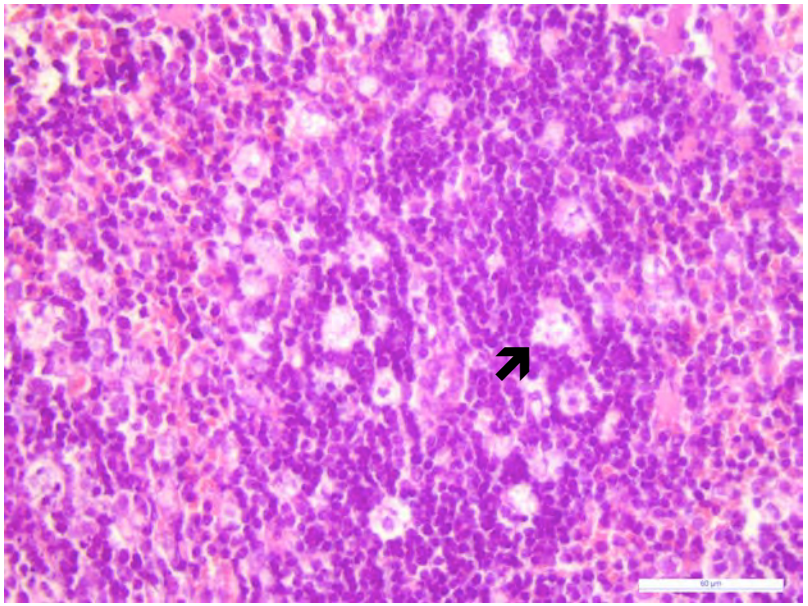

SPLEEN: moderate depletion of white pulp. Many dendritic macrophages phagocytosis of lymphocytes (tingible body macrophages) (black arrow), EE.

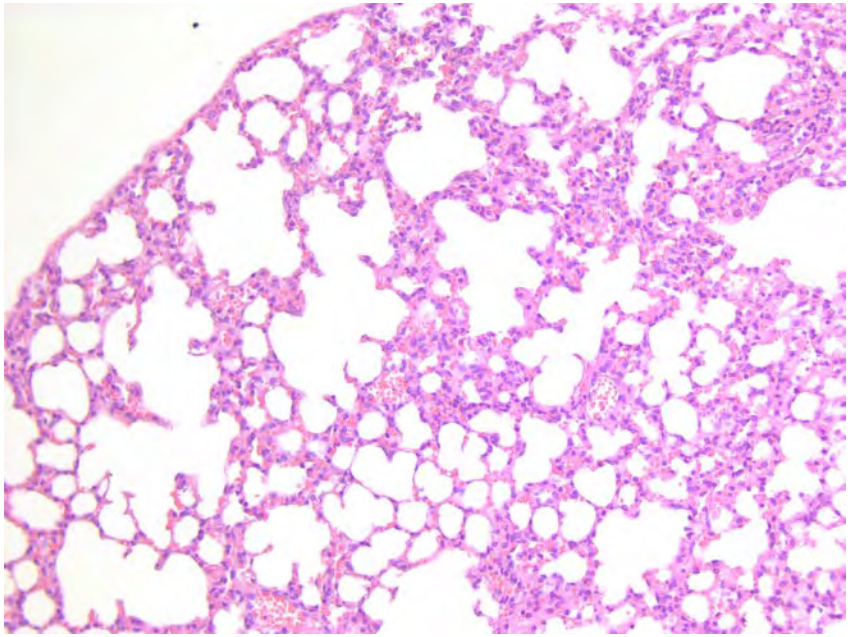

CRTL -

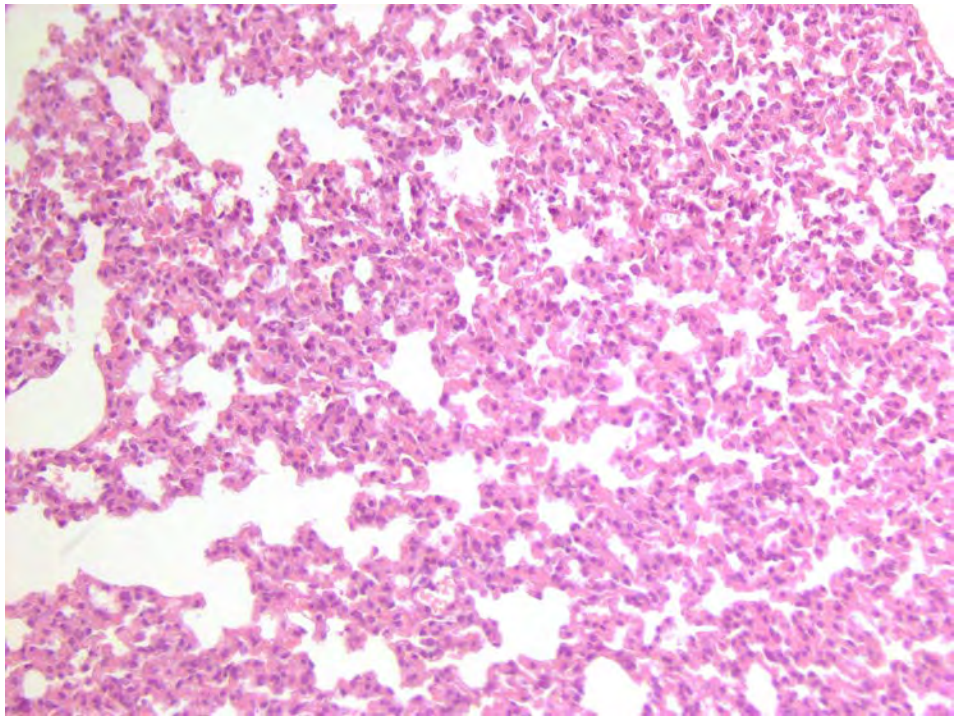

CRTL + WNV 6 dpi

Challenge

8453-12/17

D6 p.i.

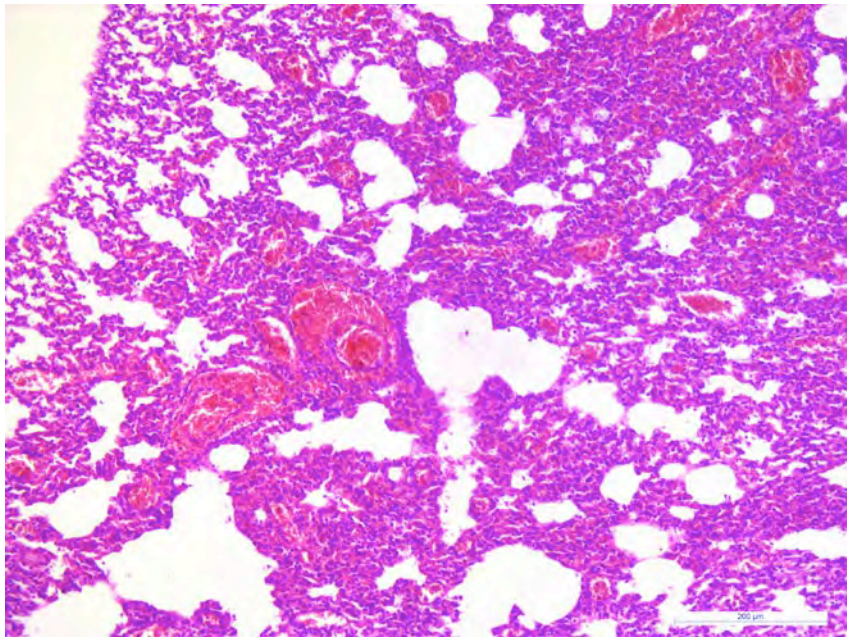

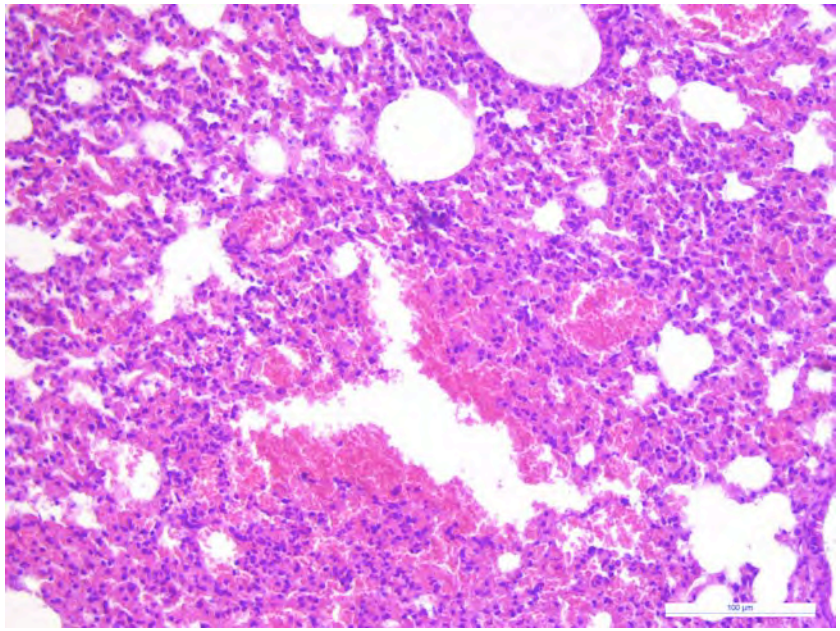

LUNG: diffuse pulmonary interstitial and alveolar hemorrhages, EE

LD, low dose
HD, high dose

Survival curve, HD USUV 2010, challenge with LD WNV

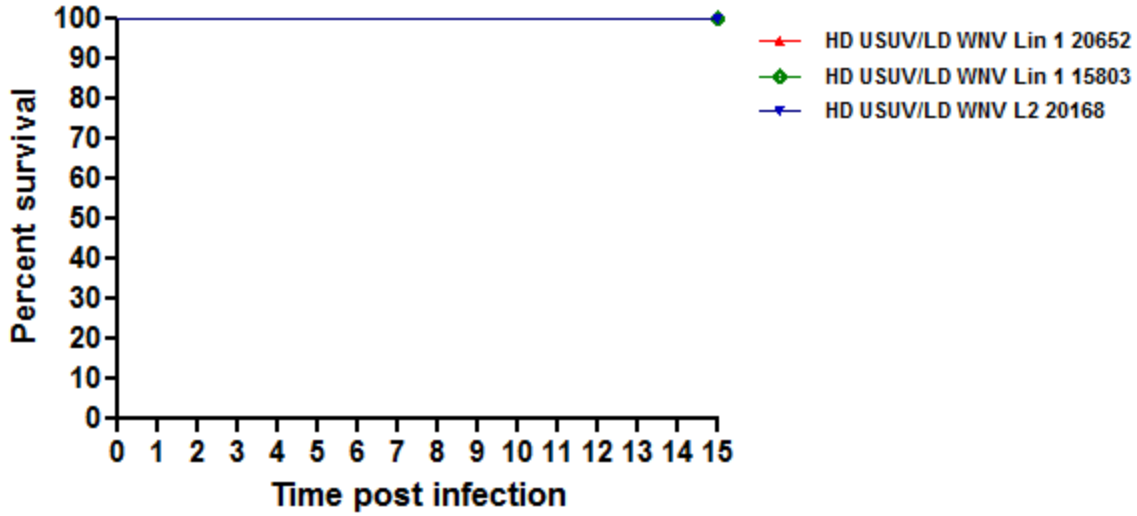

- **Mice poorly seroconverted to Usutu**
- **High titres for WNV**

competent mice

LD, low dose
HD, high dose

Survival curve, LD USUV 2010, challenge with HD WNV

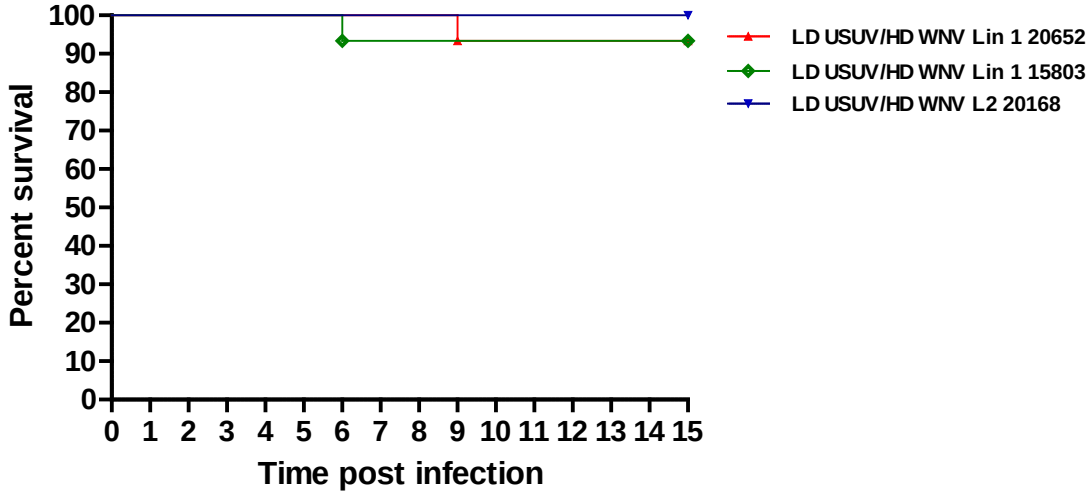

- **Mice poorly seroconverted to Usutu**
- **High titres for WNV**

competent mice

Additional USUV from 2015

LD, low dose
HD, high dose

Survival curve, HD USUV 2015, challenge with HD WNV

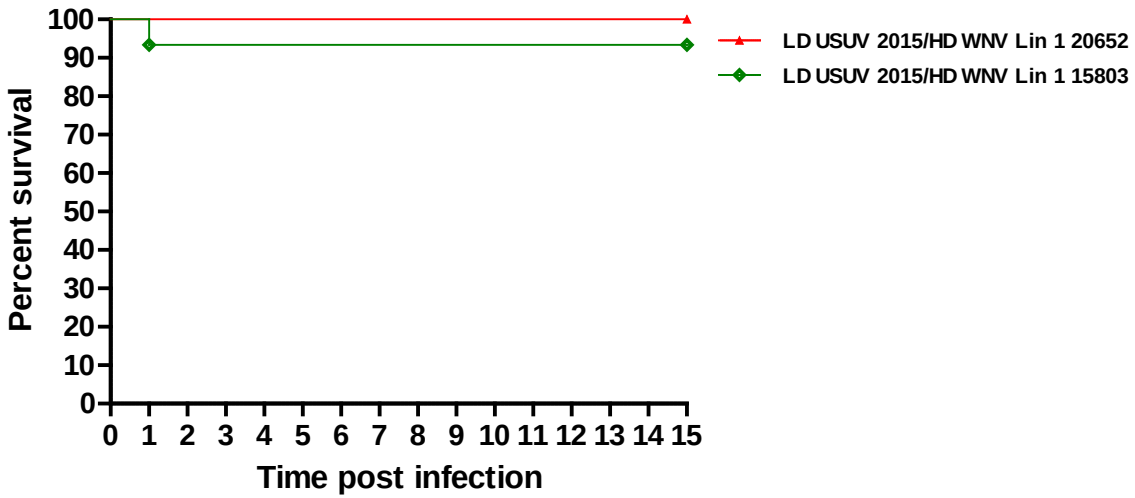

- **Mice poorly seroconverted to Usutu**
- **High titres for WNV**

competent mice

Challenge

8453-11/17 D6 p.i. (qPCR ++, LD/HD, IHC+)

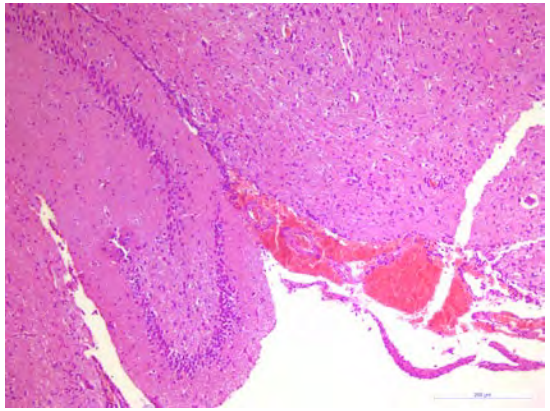

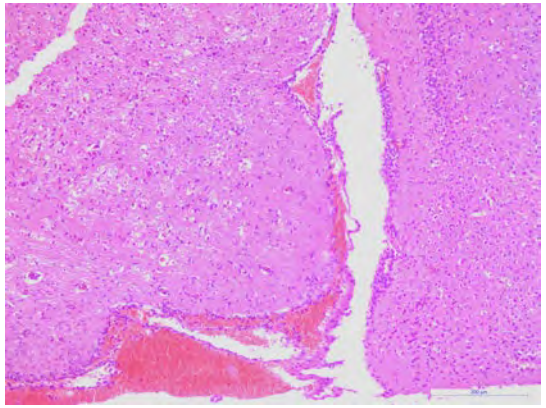

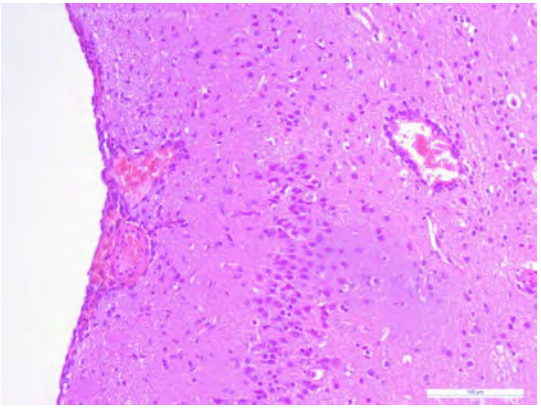

BRAIN: meningoencephalitis with exstensive meningeal hemorrages,EE.

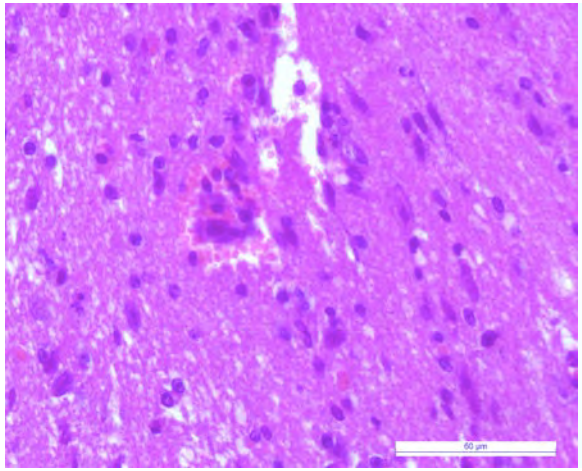

SPINAL CORD: microhemorrhage, EE.

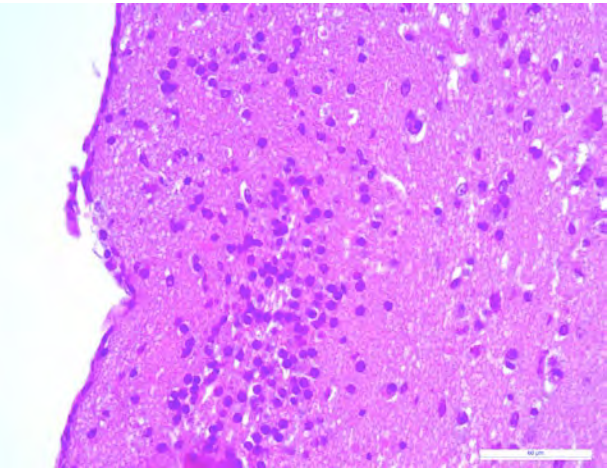

BRAIN : microglial cells infiltrate, EE.

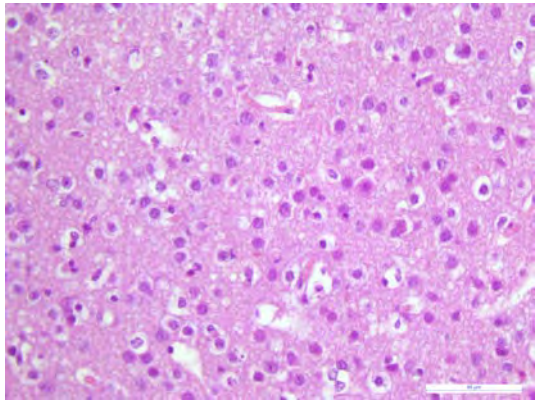

BRAIN: diffuse neurodegeneration with spongiosis, EE.

Challenge

8453-11/17
D6 p.i.

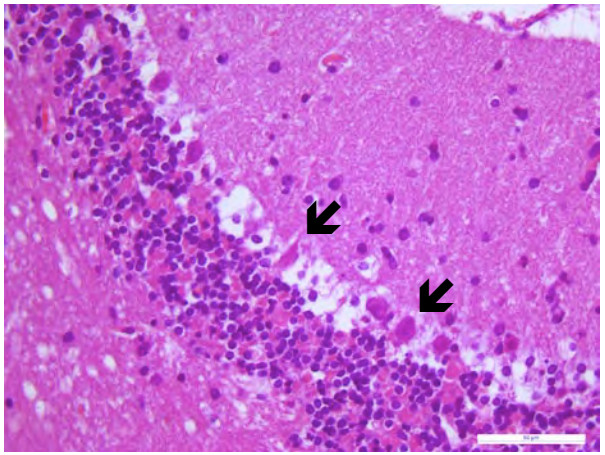

CEREBELLUM: degeneration of Purkinjie cells (arrows), EE

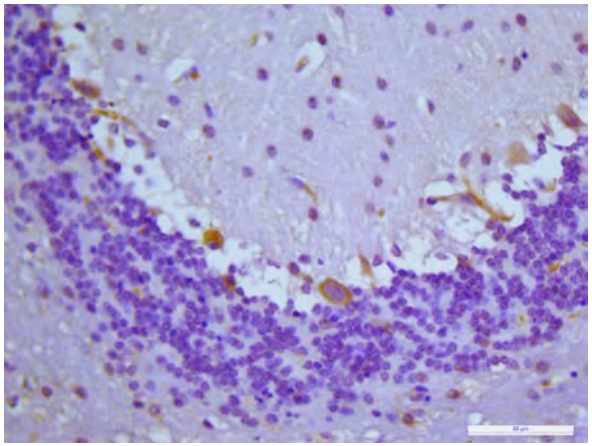

CEREBELLUM: WNV antigen in Purkinjie cells, IHC.

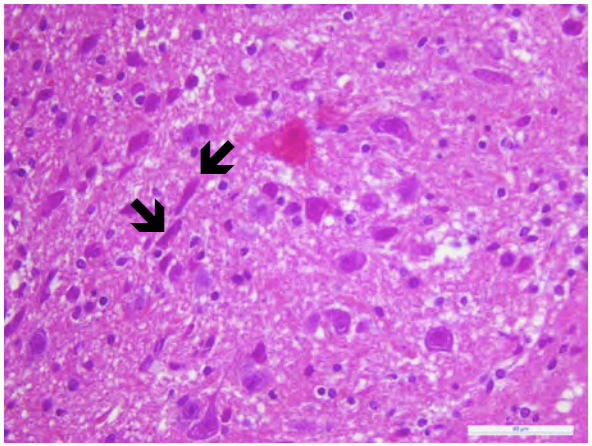

BRAIN: many erosinophilic shrunken neurons (arrows), EE.

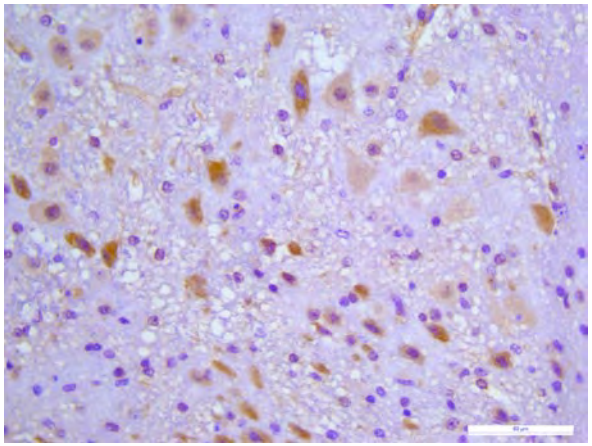

BRAIN: WNV antigen in large neurons, IHC.

Challenge

-11/

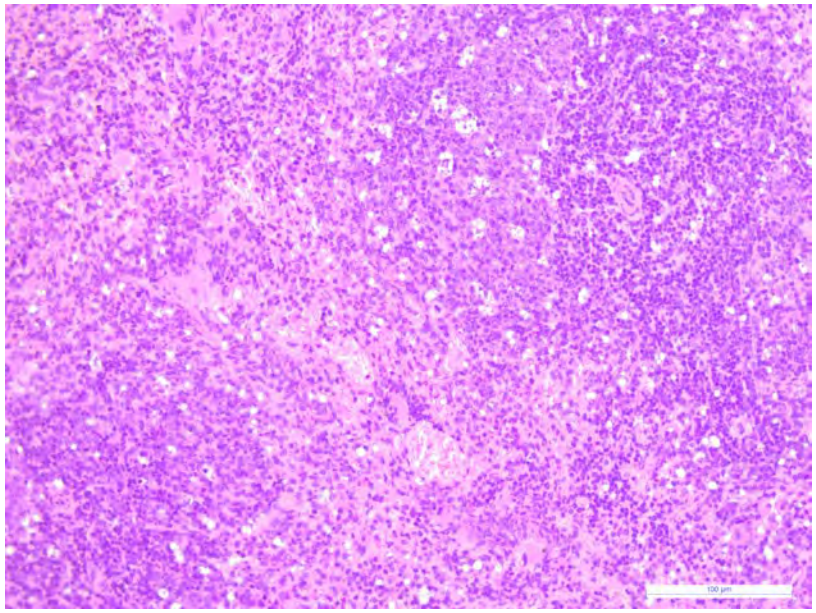

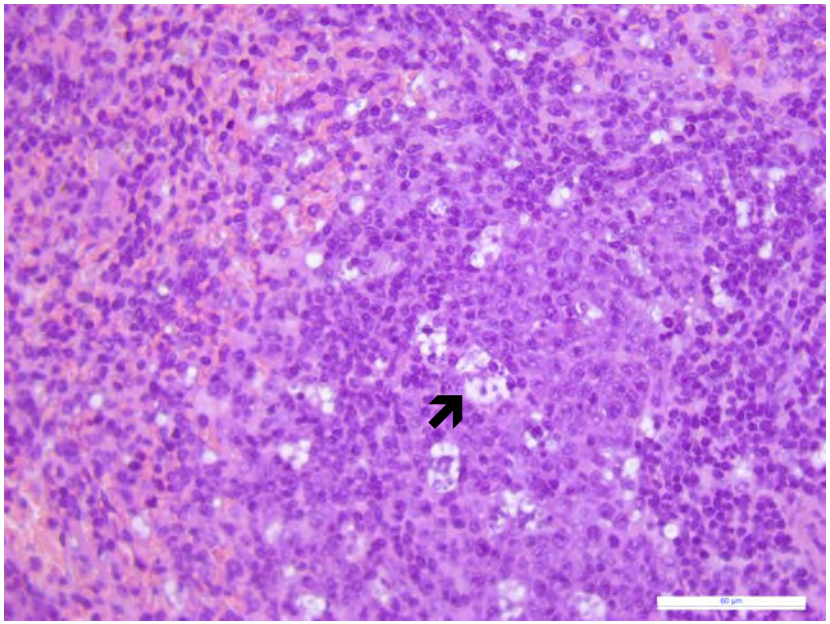

SPLEEN: moderate depletion of white pulp. Dendritic macrophages phagocytosis of lymphocytes (tingible body macrophages) (black arrow), EE.

Succumbed mice after challenge

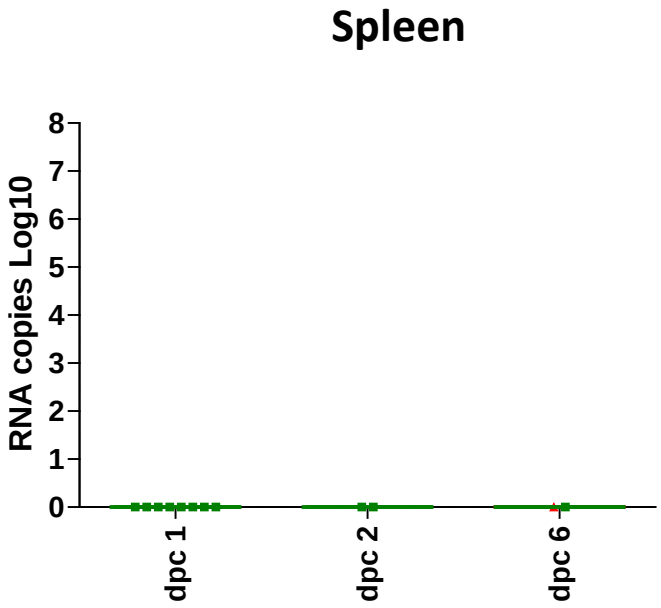

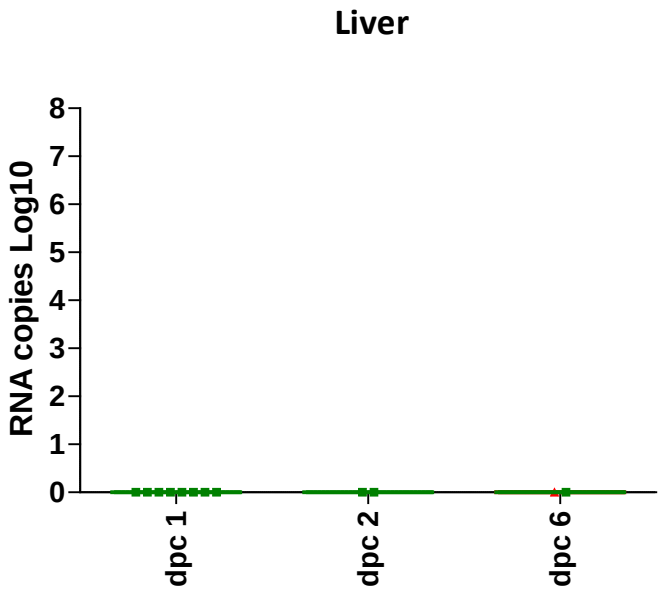
Liver
RNA copies Log10
8
7
6
5
4
3
2
1
0
dpc 1
dpc 2
dpc 6

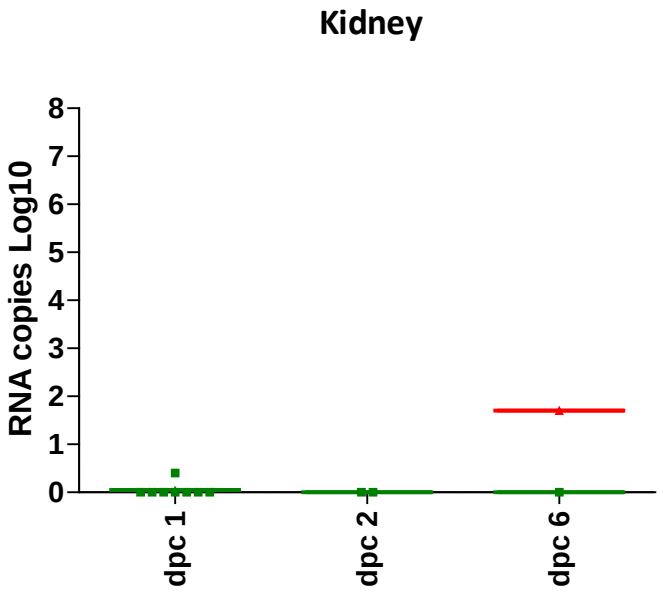
Kidney
RNA copies Log10
8
7
6
5
4
3
2
1
0
dpc 1
dpc 2
dpc 6

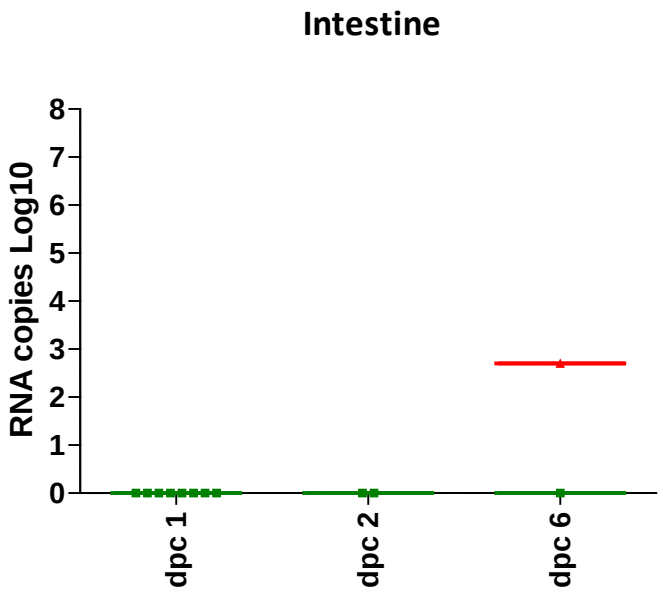
Intestine
RNA copies Log10
8
7
6
5
4
3
2
1
0
dpc 1
dpc 2
dpc 6

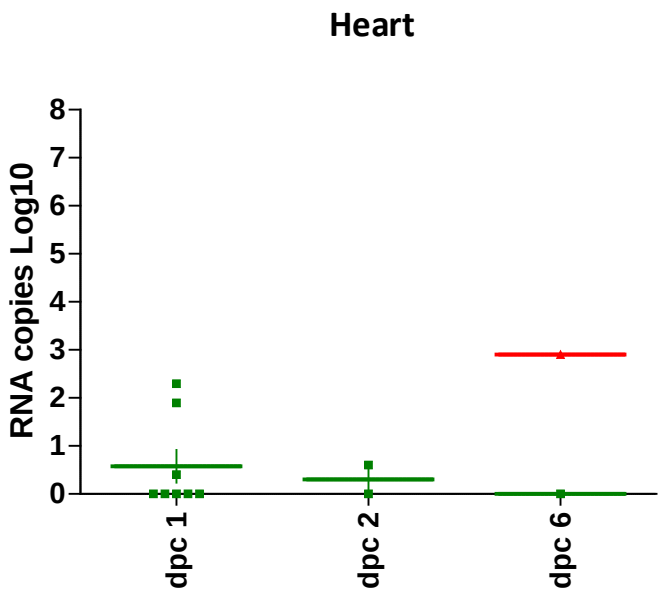
Heart
RNA copies Log10
8
7
6
5
4
3
2
1
0
dpc 1
dpc 2
dpc 6

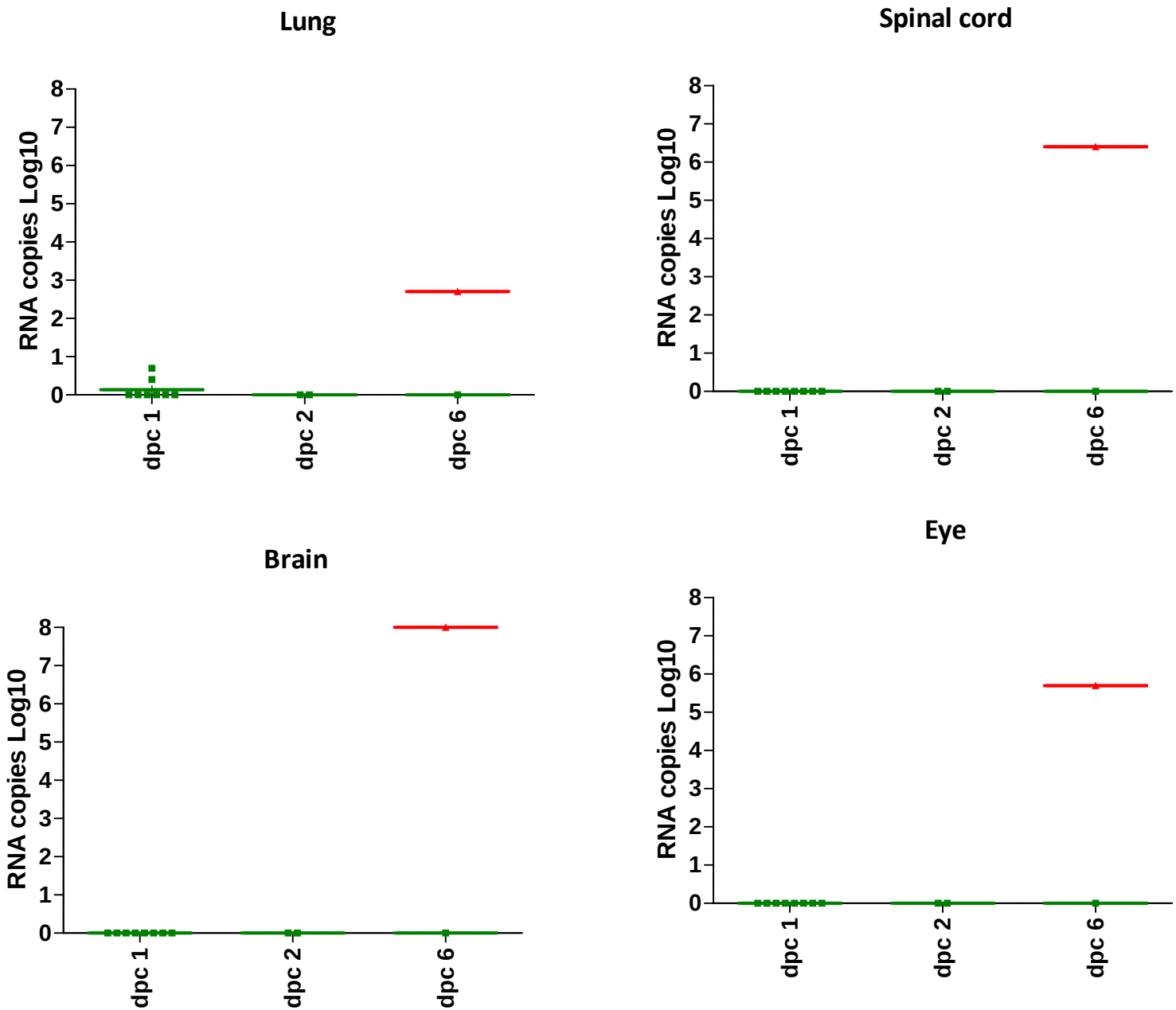
Lung
RNA copies Log10
0
1
2
3
4
5
6
7
8
dpc 1
dpc 2
dpc 6
Spinal cord
RNA copies Log10
0
1
2
3
4
5
6
7
8
dpc 1
dpc 2
dpc 6
Brain
RNA copies Log10
0
1
2
3
4
5
6
7
8
dpc 1
dpc 2
dpc 6
Eye
RNA copies Log10
0
1
2
3
4
5
6
7
8
dpc 1
dpc 2
dpc 6

IFNAR
MODEL FOR USUV

IFNAR

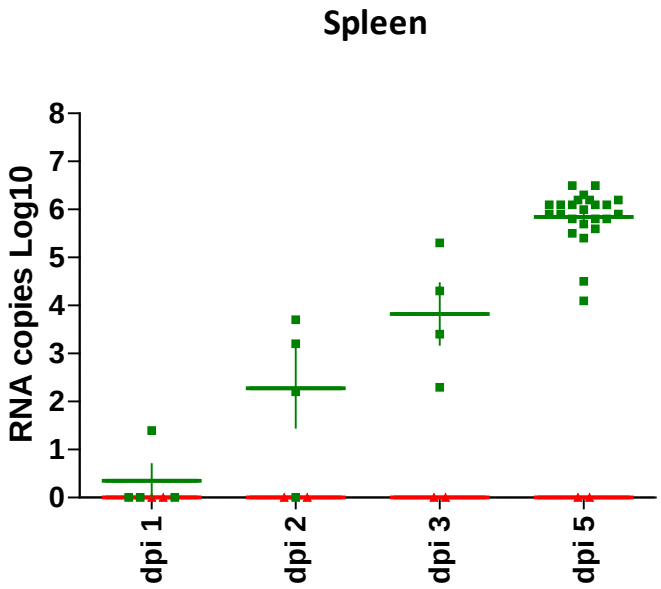
Spleen
RNA copies Log10
0
1
2
3
4
5
6
7
8
dpi 1
dpi 2
dpi 3
dpi 5

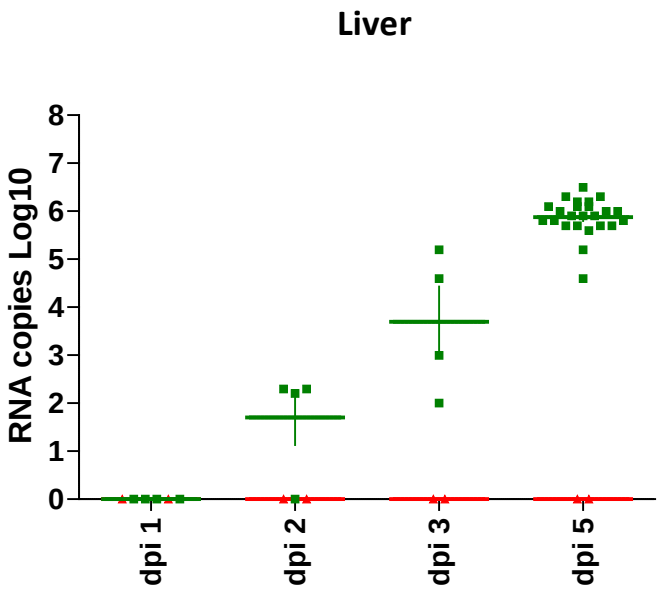
Liver
RNA copies Log10
0
1
2
3
4
5
6
7
8
dpi 1
dpi 2
dpi 3
dpi 5

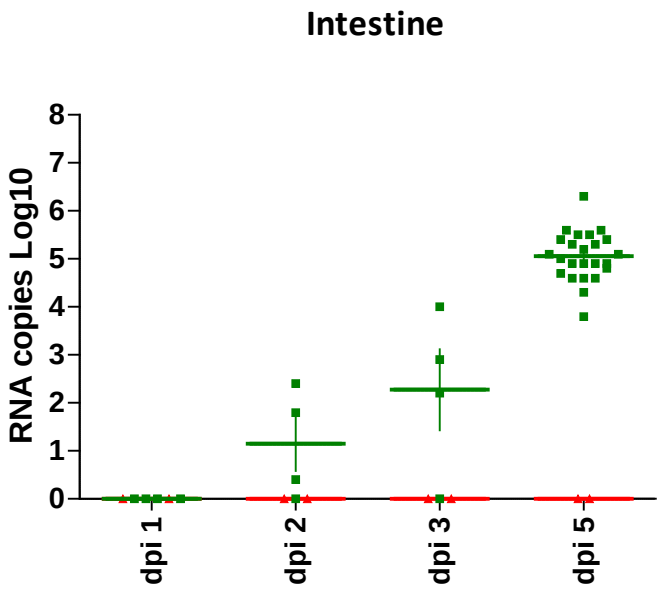
Intestine
RNA copies Log10
0
1
2
3
4
5
6
7
8
dpi 1
dpi 2
dpi 3
dpi 5

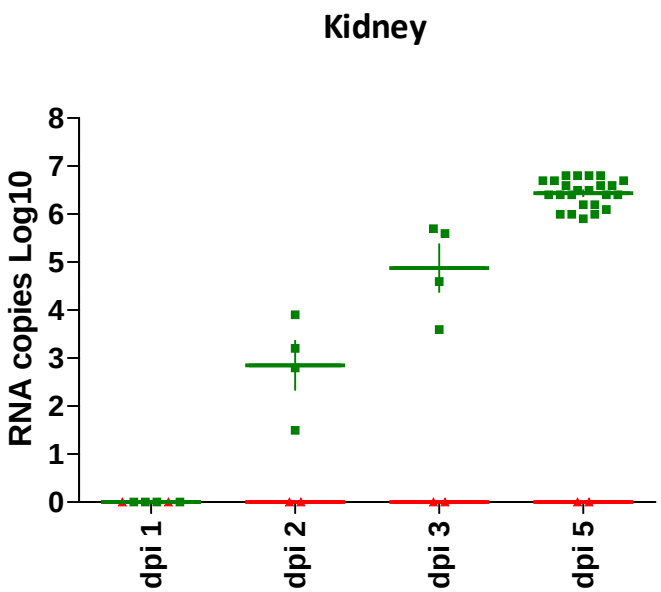
Kidney
RNA copies Log10
0
1
2
3
4
5
6
7
8
dpi 1
dpi 2
dpi 3
dpi 5

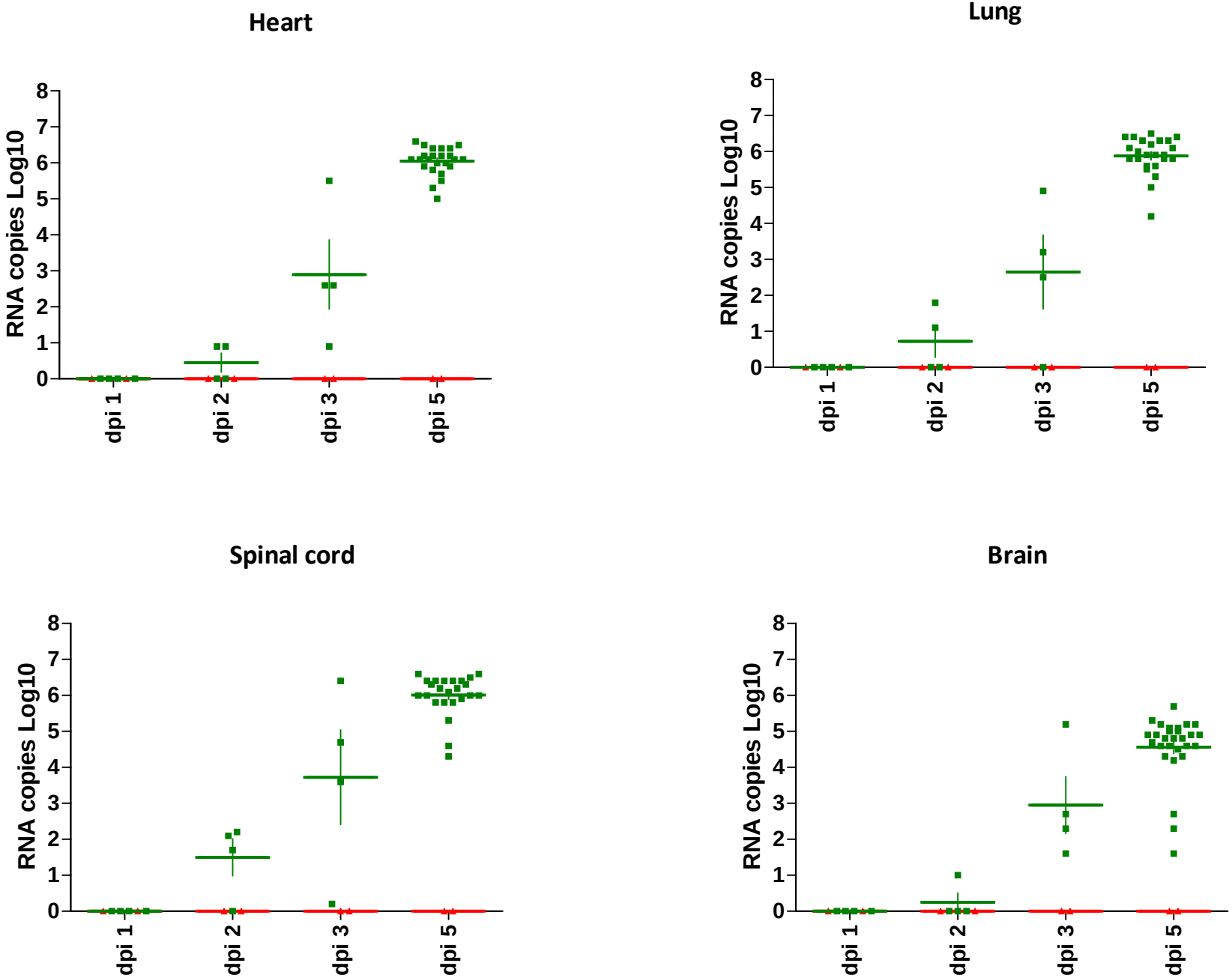
Heart
Lung
Spinal cord
Brain
RNA copies Log10
0
1
2
3
4
5
6
7
8
dpi 1
dpi 2
dpi 3
dpi 5

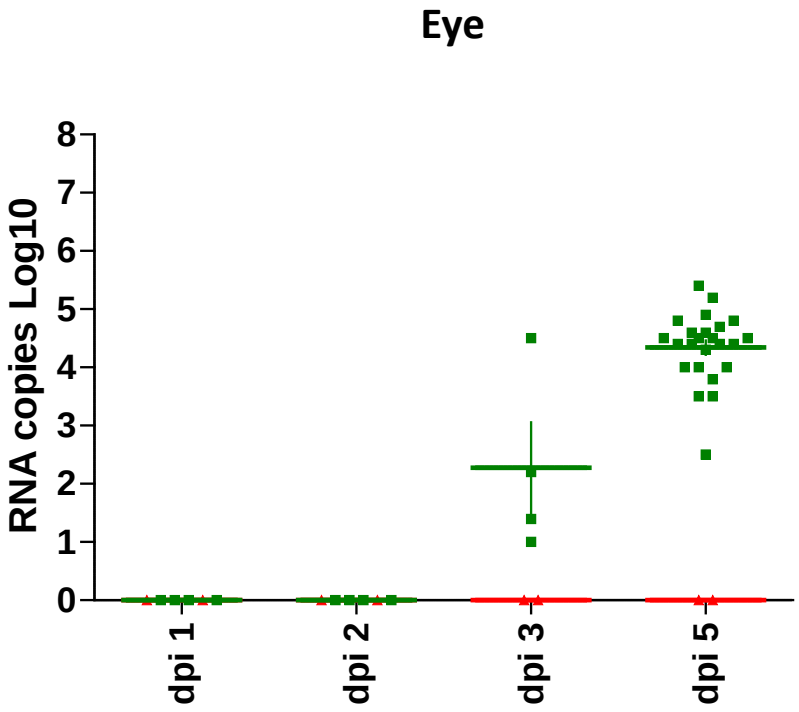
Eye
RNA copies Log10
8
7
6
5
4
3
2
1
0
dpi 1
dpi 2
dpi 3
dpi 5

Miocardite in 75%

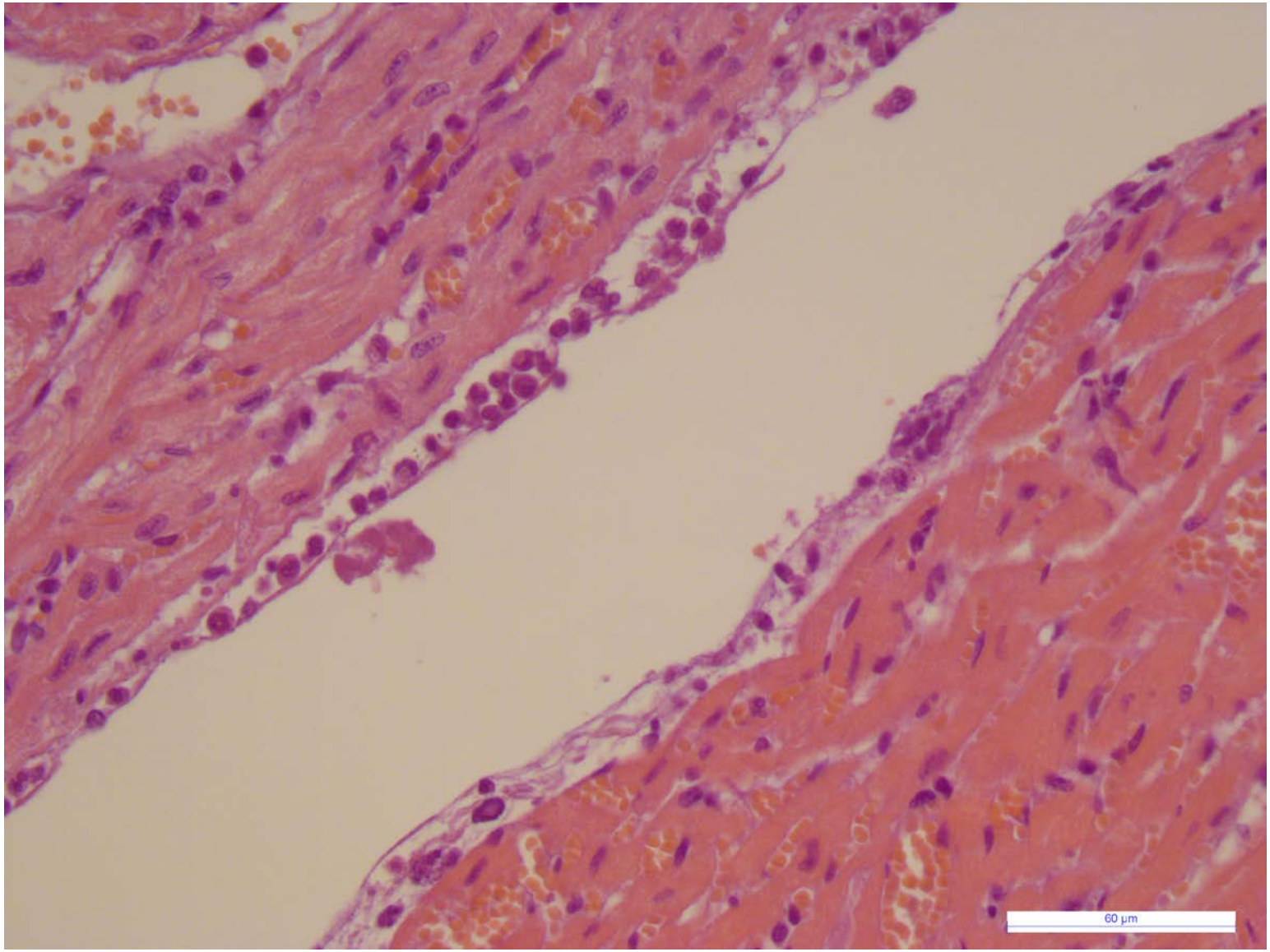

RUNNING EXPERIMENTS

- qPCR and IHC in HD WNV infected mice
- Infectious clones (RG)
- Chimeric viruses WNV/Usutu
- Serum + challenge experiments

GRAZIE PER L’ATTENZIONE